

Maxillary tuberosity fracture and subconjunctival hemorrhage following extraction of maxillary third molar

**Kanagasabapathy
Thirumurugan,
Munzanoor Rathinam
Ramesh Babu,
Gnanasekaran Arun
Prasad, Kannan Sankar**

Department of Oral and Maxillofacial Surgery, Mahatma Gandhi Post Graduate Institute of Dental Science, Pondicherry, India

Address for correspondence:

Dr. K. Thirumurugan, Department of Oral and Maxillofacial Surgery, Mahatma Gandhi Post Graduate Institute of Dental Science, Pondicherry - 605 006, India. E-mail: thirumurugan_k2000@yahoo.co.in

Abstract

Extraction of teeth is the most common minor surgical procedure performed. Complication of extraction ranges from periodontal injury to fracture of jaw in the mandible and fracture of tuberosity and oroantral communication in the maxilla. Subconjunctival hemorrhage after extraction of maxillary molar is a very rare complication, and so far, only one case is reported in the literature. We report a case of subconjunctival hemorrhage with maxillary tuberosity fracture after maxillary third molar extraction.

Key words: *Maxillary tuberosity fracture, subconjunctival hemorrhage, third molar extraction*

INTRODUCTION

Extraction of the tooth requires that the surrounding alveolar bone be expanded to allow an unimpeded pathway for tooth removal. Upper third molar lies just in front and within the maxillary tuberosity. The fracture of a large portion of bone in the maxillary tuberosity area is a situation of special concern, which can result in torrential hemorrhage due to close proximity of significant vessels to the area. Maxillary tuberosity is especially important for the stability of upper denture and may cause oroantral communication if fractured.^[1-3] The etiology of subconjunctival ecchymosis is traumatic and non-traumatic in origin. The most common traumatic condition, which is a distinctive and frequent finding, is facial trauma involving the fractures of the zygoma. Weisenbaugh noted this symptom in 70% of the cases. In addition, cosmetic surgery, barotrauma, and vigorous coughing can also cause subconjunctival ecchymosis. The non-traumatic causes include systemic hypertension, disseminated intra-vascular coagulation, and certain blood diathesis like von Willebrand disease, in which spontaneous hemorrhage is seen.^[4-6] The purpose of this article is to present a rare case of

subconjunctival hemorrhage with maxillary tuberosity fracture following extraction of upper third molar and to discuss its etiology and management.

CASE REPORT

A 52-year-old man was referred to our department by a private dental practitioner after attempted extraction of left upper third molar with peri-orbital and subconjunctival ecchymosis of left eye and hematoma of left maxillary tuberosity and buccal mucosa. Detailed history revealed that the patient noticed redness in his left eye on the day of the dental procedure. His medical history revealed that he has vitiligo and was undergoing treatment for the same for the past 3 years. Patient denied any bleeding disorders and reported that he had undergone uneventful extraction few months back. There was no significant personal and family history. On examination, patient's vital signs were all within normal limits with no neurological deficit.

Extra oral examination revealed peri-orbital and subconjunctival ecchymosis with posterior limit and patches of hypopigmentation (vitiligo) around the peri-oral, nasal,

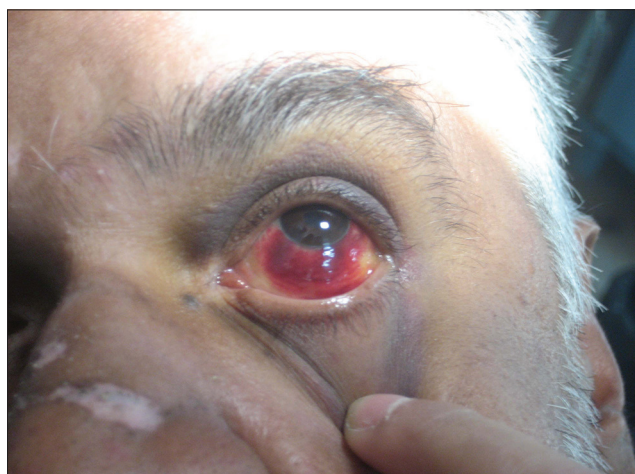

Figure 1: This image shows peri-orbital ecchymosis and subconjunctival hemorrhage

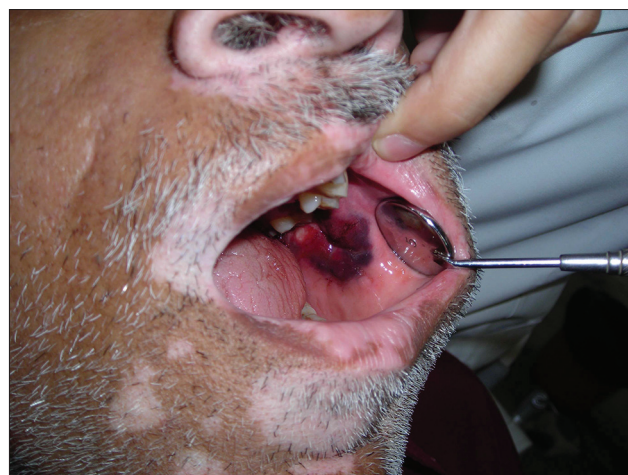

Figure 2: Intra-oral photograph reveals ecchymosis in buccal mucosa

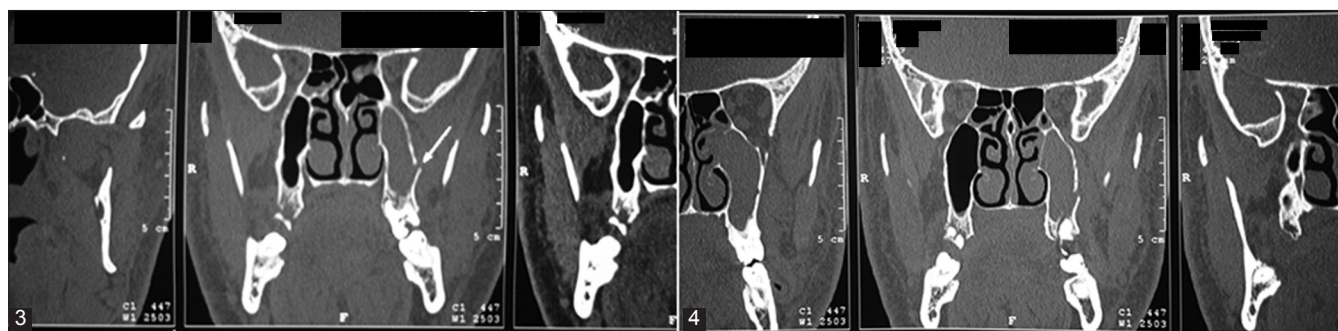


Figure 3 and 4: Computerized tomography scan reveals grossly decayed maxillary third molar with fractured maxillary tuberosity and sinus opacification

and neck region [Figure 1]. His vision and movements of the globe were normal. Intra oral examination revealed a large hematoma in the region of left maxillary tuberosity region and a mobile upper third molar [Figure 2]. CT scan revealed a grossly decayed left upper third molar with fractured posterolateral wall of left maxillary sinus and opacification [Figures 3 and 4]. After consultation with ophthalmologist, conservative management with antibiotic eye drops and benzalkonium chloride were prescribed. Patient vision monitored regularly for the visual disturbances or progressive loss of vision.

Left upper third molar was surgically removed by loosening the gingival cuff and removing as little bone as possible to retain the tuberosity with the periosteum. Tissues were closed with watertight closure. Patient was followed up for 3 weeks, at the end of which there was a complete resolution of subconjunctival followed by peri-orbital ecchymosis.

DISCUSSION

The complications of intra-alveolar extraction of maxillary teeth that are documented include displacement of the teeth or roots into the maxillary sinus, fracture of the maxillary alveolus and fracture of the maxillary tuberosity, oro-antral communication, and intra-orbital hematoma. The extraction of a tooth requires that the surrounding alveolar bone be expanded to allow an unimpeded pathway for tooth removal. However, in general, small bone parts are removed with the tooth instead of expanding. Fracture of a large portion of bone in the maxillary tuberosity area is a situation of special concern. The maxillary tuberosity is especially important for the stability of maxillary denture. Large fractures of the maxillary tuberosity should be viewed as a grave complication.^[7] The etiologic factors responsible for fractured maxillary tuberosity during extraction of upper molars are a large maxillary sinus with thin walls, a tooth with large divergent roots or an abnormal number of roots, and dental anomalies such as tooth fusion, tooth isolation, over-eruption, ankylosis, and hypercementosis of upper molar teeth. A chronic apical infection of the affected tooth may result in bone sclerosis and render the bone of the tuberosity more liable to fracture.^[1-3]

Shah and Bridgman presented a case about the fact that an extraction complicated by lateral and medial pterygoid tethering of a fractured maxillary tuberosity and delivery of the tooth and bone fragment under local anesthesia were unable to be achieved because of pain, brisk bleeding, and tethering by lateral and medial pterygoid muscles. They emphasized that when this complication is

recognized by the general dentist, the maxillary tuberosity should not be removed and the patient must be referred to a special unit.^[3] Fragile vessels in the region of the posterior maxilla and tuberosity are easily ruptured when bone is fractured and separated from its periosteum. This can result in torrential bleeding and a life-threatening situation.^[8]

Ngeow defended the conservative approach to the large tuberosity fractures and reported an alternative method that if the bony fragment is large, the tooth is grasped with a pair of molar forceps. In this way, the fractured tuberosity fragment is stabilized and a sharp Coupland periosteal elevator is then inserted into the distobuccal cervical area of the tooth and used to separate the alveolar bone segment from the roots of the tooth. The major therapeutic goal of management is to salvage the fractured bone in place and to provide the best possible environment for healing. Prevention of this complication is the best option and should include a proper preoperative examination and right surgical plan.^[9]

Routine treatment of the large maxillary tuberosity fractures is to stabilize the mobile part (s) of bone with one of rigid fixation techniques for 4 to 6 weeks. Following adequate healing, a surgical extraction procedure may be attempted. However, if the tooth is infected or symptomatic at the time of the tuberosity fracture, the extraction should be continued by loosening the gingival cuff and removing as little bone as possible while attempting to avoid separation of the tuberosity from the periosteum. If the attempt to remove the attached bone is unsuccessful and the infected tooth is delivered with the attached tuberosity, the tissues should be closed with watertight sutures because there may not be a clinical oro-antral communication.^[4,10] This mode of management was followed in our case. The surgeon may elect to graft the area after 4 to 6 weeks of healing and postoperative antibiotic therapy. If the tooth is symptomatic, but there is no frank sign of purulence or infection, the surgeon may elect to attempt to use the attached bone as an autogenous graft.

In this case, the peri-orbital and subconjunctival ecchymosis has occurred as a result of maxillary tuberosity fracture and the ensuing bleeding from the adjacent vessels. According to Warburton and Brahim who reported a case of intra-orbital hematoma after removal of upper third molar, the hemorrhage must have occurred from one of the tributary vessels of the pterygoid plexus such as the deep facial vein, the posterior superior alveolar vessels, or even from the plexus itself. This could have resulted in bleeding into the pterygomaxillary and infra-temporal spaces, which

communicate with the intra-orbital compartment via the inferior orbital fissure. This provides a pathway, through which the hematoma in the infra-temporal fossa might have extended into the orbit.^[11]

Management of subconjunctival hemorrhage in our case is the same conservative treatment with antibiotic eye drops and lubricants as like subconjunctival hemorrhage in zygoma fractures.

CONCLUSION

Maxillary tuberosity fracture is one of the major complications of maxillary third molar extraction. In our case, it was associated with subconjunctival hemorrhage. We conclude that maxillary tuberosity fracture may be associated with subconjunctival hemorrhage and become even more complicated to manage if atraumatic principles are not followed while extracting upper third molars.

REFERENCES

- Cohen L. Fractures of the maxillary tuberosity occurring during tooth extraction. *Oral Surg Oral Med Oral Pathol* 1960;13:409-11.
- Norman JE, Cannon PD. Fracture of the maxillary tuberosity. *Oral Surg Oral Med Oral Pathol* 1967;24:459-67.
- Shah N, Bridgman JB. An extraction complicated by lateral and medial pterygoid tethering of a fractured maxillary tuberosity. *Br Dent J* 2005;198:543-4.
- Fonseca RJ. *Oral and Maxillofacial Surgery*. Vol. 1. Pennsylvania: W.B. Saunders; 2000. p. 430.
- Fukuyama J, Hayasuka S, Yamada K, Setogawa T. Causes of subconjunctival haemorrhage. *Ophthalmologica* 1990;200:63-7.
- Kumar RA, Moturi K. Subconjunctival ecchymosis after extraction of maxillary molar teeth: A case report. *Dent Traumatol* 2010;26:298-300.
- Polat HB, Ay S, Kara MI. Maxillary tuberosity fracture associated with first molar extraction: A case report. *Eur J Dent* 2007;1:256-9.
- Bertram AR, Rao AC, Akbiyik KM, Haddad S, Zoud K. Maxillary tuberosity fracture: A life-threatening haemorrhage following simple exodontia. *Aust Dent J* 2011;56:212-5.
- Altuğ HA, Sahin S, Sencimen M, Dogan N. Extraction of upper first molar resulting in fracture of maxillary tuberosity. *Dent Traumatol* 2009;25:e1-2.
- Chrcanovic BR, Freire-Maia B. Considerations of maxillary tuberosity fractures during extraction of upper molars: A literature review. *Dent Traumatol* 2011;27:393-8.
- Warburton G, Brahim JS. Intraorbital hematoma after removal of upper third molar: A case report. *J Oral Maxillofac Surg* 2006;64:700-4.

How to cite this article: Thirumurugan K, Ramesh Babu MR, Prasad GA, Sankar K. Maxillary tuberosity fracture and subconjunctival hemorrhage following extraction of maxillary third molar. *J Nat Sc Biol Med* 2013;4:242-5.

Source of Support: Nil. **Conflict of Interest:** None declared.

Access this article online

Quick Response Code:



Website:

www.jnsbm.org

DOI:

10.4103/0976-9668.107317