

Response of human dental pulp to calcium hydroxide paste preceded by a corticosteroid/antibiotic dressing agent

Elisa Maria Aparecida Giro¹, Juliana Oliveira Gondim², Josimeri Hebling¹, Carlos Alberto de Souza Costa³

¹ DDS, MSc, PhD, Professor, Department of Orthodontics and Pediatric Dentistry, School of Dentistry of Araraquara, Universidade Estadual Paulista - UNESP, Araraquara, SP, Brazil

² DDS, MSc, Assistant Professor, Department of Dentistry, School of Dentistry, Federal University of Ceará, Sobral, Fortaleza, CE, Brazil; Graduate Student, Department of Orthodontics and Pediatric Dentistry, School of Dentistry of Araraquara, Universidade Estadual Paulista - UNESP, Araraquara, SP, Brazil

³ DDS, MSc, PhD, Professor, Department of Physiology and Pathology, School of Dentistry of Araraquara, Universidade Estadual Paulista - UNESP, Araraquara, SP, Brazil

Abstract

Aim: To evaluate the treatment with corticosteroid/antibiotic dressing in pulpotomy with calcium hydroxide. **Methods:** Forty-six premolars were pulpotomized and randomly assigned into 3 groups. In Group I pulpal wound was directly capped with calcium hydroxide, and Group II and Group III received corticosteroid/antibiotic dressing for 10 min or 48 h, respectively, before pulp capping. Teeth were processed for histological analysis after 7, 30 or 60 days to determine inflammatory cell response, tissue disorganization, dentin bridge formation and presence of bacteria. Attributed scores were analyzed by Kruskal-Wallis and Mann-Whitney tests ($\alpha=0.05$). **Results:** On the 7th day, all groups exhibited dilated and congested blood vessels in the tissue adjacent to pulpal wound. The inflammatory cell response was significantly greater in Group III ($p<0.05$). On the 30th day, in all groups, a thin dentin matrix layer was deposited adjacent to the pulpal wound and a continuous odontoblast-like cell layer underlying the dentin matrix was observed. On the 60th day, all groups presented a thick hard barrier characterized by an outer zone of dystrophic calcification and an inner zone of tubular dentin matrix underlined by a defined odontoblast-like cell layer. **Conclusions:** Within the limitations of present study, considering that the treatment was performed in healthy teeth, it may be concluded that the use of a corticosteroid/antibiotic dressing before remaining tissue protection with calcium hydroxide had no influence on pulp tissue healing.

Keywords: calcium hydroxide, corticosteroid, dental pulp capping, permanent dentition, pulpotomy.

Introduction

The application of antiinflammatory agents on exposed pulp tissue in an attempt to prevent or minimize inflammatory reaction and to favor healing has been investigated for a long time¹⁻⁷. Corticosteroid can be used as a dressing agent for deep cavities and exposed pulp tissue in order to control the inflammatory pulp response and reduce postoperative pain^{1,3,8-10}. However, there is no consensus in the dental literature concerning the use of this medicament^{1-5,8}.

Topic corticosteroid application for 5 min on the cavity floor did not significantly change intrapulpal pressure when compared to healthy teeth². The

Received for publication: June 18, 2009

Accepted: June 21, 2010

Correspondence to:

Elisa Maria Aparecida Giro
Departamento de Clínica Infantil, Faculdade de
Odontologia de Araraquara – UNESP
Rua Humaitá, 1680 – Centro. CEP:14801-903
CP: 331, Araraquara, São Paulo, Brasil
Phone:+ 55 16 33016336; fax:+55 16 33016329
E-mail: egiro@foar.unesp.br

therapeutic effect of a corticosteroid agent seems to depend upon its potency, concentration and ability to diffuse into connective tissue. Otosporin[®], one of the commercial denominations of hydrocortisone/antibiotic association, presents high displacement capacity in dentin in comparison to other corticosteroid agents available to different therapies⁶. This product has been reported to prevent intense inflammatory reaction, cause no pulp damage when applied as a dressing agent in exposed pulps and preserve pulp vitality, showing a mild inflammatory reaction restricted to the superficial pulp zone underneath the pulp capping site³. On the other hand, the effects of corticosteroid agents have been questioned when they are applied for a long period because inhibition of collagen synthesis and interference with pulp recovery may occur in this situation¹¹.

Calcium hydroxide has been indicated as the material of choice to treat exposed pulp tissue because it presents biocompatibility, antibacterial activity and is able to induce mineralized barrier formation^{7,12-15}. Studies have shown that the high pH values of this material when in contact with pulp tissue causes coagulation necrosis, which stimulates mineralized tissue formation^{7,12-13,15-17}.

The use of calcium hydroxide for direct pulp capping is supported by several studies^{3,7}. However, considering that the mechanical trauma produced during pulpotomy therapy results in mild inflammatory pulp response, few clinical and histopathologic studies have investigated the use of corticosteroid before direct pulp capping³⁻⁴.

The aim of this *in vivo* study was to evaluate pulp healing in teeth subjected to corticosteroid/antibiotic dressing agent application prior to direct pulp capping with calcium hydroxide paste.

Material and methods

For this study, 46 intact, caries-free and periodontally healthy premolars scheduled to be extracted for orthodontic reasons (28 maxillary and 18 mandibular) were obtained from 23 patients aged between 12 and 16 years. All patients enrolled in the trial were attending the Pediatric Dentistry Clinic of the Dental School of Araraquara, Brazil, and none of them were using medicines or have any systemic disease.

After receiving full explanation about the experimental rationale, clinical procedures and possible risks, parents of all volunteers were asked to carefully read the research protocol before signing the informed consent form. Both the consent form and the research protocol were previously submitted and approved by the Human Research Ethics Committee of the São Paulo State University – UNESP, Brazil (Protocol # 52/99).

The teeth were examined clinically and radiographically for the presence of caries or periapical pathology, and were polished with rubber cup and prophylactic paste at low speed. Local anesthesia was administered (2% mepivacaine, DFL Ind. e Comércio Ltda, Rio de Janeiro, RJ, Brazil) and rubber dam isolation was provided followed by antisepsis with 70% alcohol.

Pulp chambers were opened under aseptic conditions

with #4 round bur (Beavers Dental Div. of Sybron Canada, Ontario, Canada) at high speed and under irrigation with sterile cooled water. After pulp exposure, the coronary pulp tissue was carefully cut with a sharp dentin spoon. Saline solution and sterile cotton pellets were used to control hemorrhage. Teeth were randomly assigned to 3 groups: Group I (control), Group II (10-min Otosporin[®] application) and Group III (48-h Otosporin[®] application).

Group I (n=14 teeth; 7-day period = 6 teeth, 30-day period = 4 teeth and 60-day period = 4 teeth):

In this group, calcium hydroxide paste was directly applied onto the pulp wound with a sterile instrument and gently compressed with sterile cotton pellets. This pulp-capping agent was prepared by mixing 120 mg of calcium hydroxide powder (calcium hydroxide p.a.; Merck KGaA, Darmstadt, Germany) with 60 µL of sterile distilled water. No dressing agent was applied before pulp capping. Then, a hard-setting calcium hydroxide cement (Dycal; Dentsply, Milford, DE, USA) hand-mixed according to the manufacturer's instruction was applied, followed by placement of a reinforced zinc-oxide and eugenol hard-setting cement base (IRM; Dentsply Indústria e Comércio Ltda., Petrópolis, RJ, Brazil), and cavity restoration with amalgam (Permite; SDI, Southern Dental Industries, Australia).

Group II (n=16 teeth; 7-day period = 6 teeth, 30-day period = 5 teeth and 60-day period = 5 teeth):

In this group, a sterile cotton pellet embedded with corticosteroid/antibiotic dressing agent (Otosporin[®]; Glaxo Wellcome S.A., Rio de Janeiro, RJ, Brazil) was applied for 10 min on the pulp wound, and then removed with sterile cotton pliers. The pulp chamber was irrigated with sterile saline and gently dried with a sterile cotton pellet. Calcium hydroxide paste was applied onto the pulp wound with a sterile instrument and gently compressed with sterile cotton pellets. Then, a hard-setting calcium hydroxide cement was applied, followed by placement of a reinforced zinc-oxide and eugenol hard-setting cement base, and cavity restoration with amalgam, as described in Group I.

Group III (n=16 teeth; 7-day period = 5 teeth, 30-day period = 6 teeth and 60-day period = 5 teeth):

In this group, a sterile cotton pellet embedded with Otosporin[®] dressing agent was applied onto the pulpal wound and the cavity was temporarily restored with reinforced zinc-oxide and eugenol hard-setting cement. After 48 h, the temporary restorative material and the cotton pellet embedded with the dressing agent were removed as previously described. Then, the pulpal wound was capped with calcium hydroxide paste and the cavity restored following the clinical sequence described for Groups I and II.

In all 3 groups, the pulpotomy procedures were performed by the same experienced operator.

After the experimental periods of 7, 30 or 60 days, teeth were extracted under local anesthesia and had their roots sectioned halfway between the cementoenamel junction (CEJ)

and the root tip with a high-speed handpiece under copious water spray cooling. Teeth were immersed for 48 h in 10% buffered formalin, decalcified in Morse's solution, dehydrated, and vacuum-embedded in wax paraffin. Six-micron-thick serial sections were cut ('820' Spencer Microtome, Carson, CA, USA) parallel to the long axis of the tooth. The sections were mounted on glass slides and stained with hematoxylin and eosin, Masson's Trichrome and Brown and Brenn technique for bacterial assessment.

All histological sections were evaluated by a previously standard-trained pathologist and the analyses conducted in a blind fashion protocol under light microscope (Carl Zeiss 62774, Oberkachen, West Germany). Each tooth was independently examined in serial sections and specific scores were attributed according to the established criteria presented in Tables 1 to 4. The attributed scores for the histological events were analyzed statistically by Kruskal Wallis and Mann-Whitney tests to determine any significant differences ($p < 0.05$) among the ranked groups and periods.

Results

The patients did not report pain or any kind of discomfort during the postoperative periods in any of the groups. The observed scores for the histological events in the different

experimental groups and periods are shown in Table 5.

7-Day Period

On the 7th day after the procedure, 6 teeth of Group I, 6 of Group II, and 5 of Group III were analyzed.

In all groups, a thick coagulation necrosis layer was observed adjacent to the pulp-capping agent, with pulp cells remaining within this necrotic tissue. In most specimens, the subjacent pulp tissue exhibited few polymorphonuclear neutrophils and few mononuclear cells. Small congested and dilated blood vessels were observed close to the coagulation necrosis or getting into this necrotic tissue (Figure 1).

In Group I (control), pulp response was characterized by a mild inflammatory reaction associated with mild deposition of dentin matrix in all 6 specimens. Stained bacteria along the outer third of lateral cavity walls were observed in 1 specimen of this group.

Group II presented histological characteristics of mild tissue disorganization. Moderate tissue disorganization was seen in only one specimen in which bacteria was evidenced along the outer third of the lateral cavity walls. In 2 specimens, elongated pulp cells (odontoblast-like cells) associated with mild deposition of dentin matrix underneath the coagulation necrosis zone was observed. In the 4 specimens that showed

Table 1. Scores attributed to the parameter *inflammatory cell response*

Score	Characterization
1	None or few scattered inflammatory cells adjacent to the pulpal wound
2	Mild inflammatory reaction characterized by the presence of polymorphonuclear (PMNs) or mononuclear leukocytes (MNLs)
3	Moderate inflammatory reaction with PMNs or MNLs comprising two thirds of the remaining radicular pulp tissue
4	Severe inflammatory cell infiltrate comprising all the radicular pulp or presence of abscess

Table 2. Scores attributed to the parameter *tissue disorganization*

Score	Characterization
1	Normal tissue
2	Mild tissue disorganization adjacent to the pulpal wound or bellow the newly deposited hard tissue barrier
3	Moderate tissue disorganization comprising two thirds of the remaining radicular pulp tissue
4	Complete tissue disorganization characterizing pulp necrosis or abscess

Table 3. Scores attributed to the parameter *reparative dentin formation*

Score	Characterization
1	Presence of elongated cells organized in monolayer associated with intense hard tissue barrier deposition beneath the pulpal wound
2	Presence of elongated cells organized in monolayer associated with moderate hard tissue barrier deposition beneath the pulpal wound
3	Presence of elongated cells organized in monolayer associated with mild deposition of dentin matrix beneath the pulpal wound
4	Absence of organized elongated cells associated with absence of hard tissue barrier formation adjacent to the pulpal wound

Table 4. Scores attributed to the parameter *stained bacteria*

Score	Characterization
1	Absence of stained bacteria
2	Presence of stained bacteria along the outer third of the cavity lateral walls
3	Presence of stained bacteria along all cavity lateral walls
4	Presence of stained bacteria along all cavity walls and within the pulp tissue

Table 5. Number of teeth for each score according to groups and periods

Groups/Periods	Histopathological events scores															
	Inflammatory cell response				Tissue disorganization				Reparative dentin formation				Stained bacteria			
	1	2	3	4	1	2	3	4	1	2	3	4	1	2	3	4
7 days	0	6	0	0	0	6	0	0	0	0	6	0	5	1	0	0
Group I																
30 days	2	2	0	0	2	2	0	0	0	4	0	0	4	0	0	0
60 days	3	1	0	0	3	1	0	0	3	1	0	0	3	1	0	0
7 days	6	0	0	0	0	5	1	0	0	0	2	4	5	1	0	0
Group II																
30 days	5	0	0	0	4	1	0	0	0	4	1	0	5	0	0	0
60 days	4	1	0	0	3	2	0	0	2	3	0	0	5	0	0	0
7 days	0	4	1	0	0	4	1	0	0	0	3	2	5	0	0	0
Group III																
30 days	5	1	0	0	5	1	0	0	0	4	2	0	4	2	0	0
60 days	4	1	0	0	4	1	0	0	4	1	0	0	4	1	0	0




Fig. 1 - (Group II; 7th day) - Pulpotomy zone with large coagulation necrotic area between material and pulp tissue (arrows). Presence of few inflammatory cells and small congested and dilated blood vessels in subjacent pulp tissue. Hematoxylin-eosin, original magnification 32X.

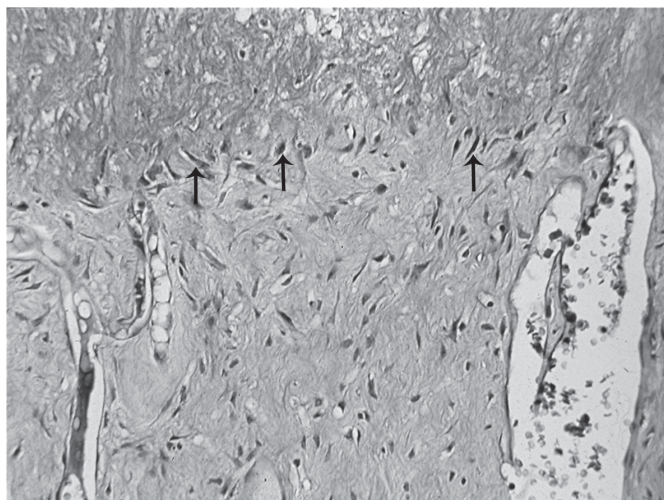


Fig. 2 - (Group III; 7th day) - Elongated cells organized in layer (arrows) in the area immediately below the coagulation necrotic zone. Large number of blood vessels in the subjacent pulp tissue. Hematoxylin-eosin, original magnification 125X.

disorganized elongated cells no dentin matrix deposition was seen.

In Group III, pulp response was similar to that of Group II. However, mild inflammatory response was observed in 4 specimens (Figure 2) and moderate inflammatory reaction was seen in 1 specimen. It should be emphasized that no microleakage was evidenced in all evaluated specimens.

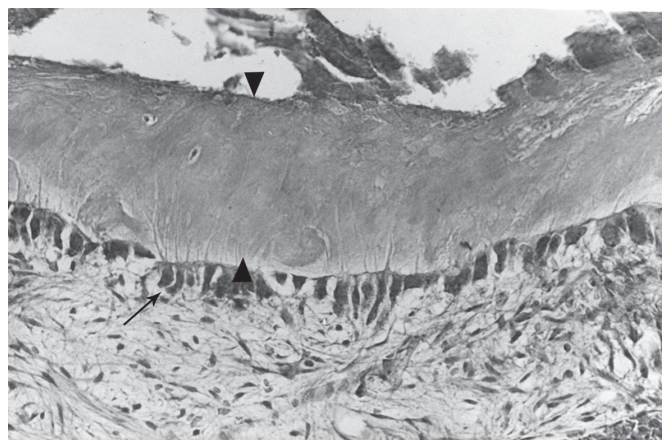


Fig. 3 - (group I; 30th day) - Moderate deposition of hard tissue subjacent to the pulp wound. Presence of odontoblast-like cells in monolayer. Hematoxylin-eosin, original magnification 280X.

30-Day Period

After 30 days of the procedure 4 teeth of Group I, 5 teeth of Group II, and 6 of Group III were analyzed.

In Group I (control), all specimens showed a monolayer of elongated cells associated with moderate deposition of hard tissue subjacent to pulp wound (Figure 3). Mild inflammatory reaction associated with mild tissue disorganization was seen in 2 out of 4 specimens.

In Group II, all specimens presented dystrophic calcification in the deepest zone of the coagulation necrosis layer. Presence of a monolayer of elongated cells (odontoblast-



Fig. 4 - (group II; 30th day) - Included cells in the midst of hard barrier tissue underlined by odontoblast-like cells (arrowheads). Absence of inflammatory characteristics in the subjacent pulp tissue. Masson Trichrome stain, original magnification 125X.

like cells) underlying the dystrophic calcification zone was noted. These differentiated elongated pulp cells were responsible for the deposition of a thin dentin matrix layer which, associated to the dystrophic calcification, characterized the moderate hard tissue barrier formation. The subjacent pulp tissue exhibited normal histological characteristics (Figure 4). Delay in the pulp repair occurred in one specimen in which calcium hydroxide remnants were displaced into pulpal space. In this specimen, heterogeneous deposition of dentin matrix associated to mild tissue disorganization was observed. No bacterial contamination in the lateral cavity walls or in the pulp tissue was observed in any of the specimens.

In Group III, stained bacteria were seen along the outer third of the lateral cavity walls in 2 specimens, in which mild dentin matrix deposition was observed. In one of these specimens, mild inflammatory response occurred associated with tissue disorganization. However, moderate hard tissue barrier formation was observed in 4 out of 5 specimens in which no inflammatory response was determined (Figure 5).

60-Day Period

After 60 days of the procedure 4 teeth of Group I, 5 teeth of Group II, and 5 of Group III were analyzed.

At this period, an intense deposition of partially calcified dentin matrix underneath the thick layer of dystrophic

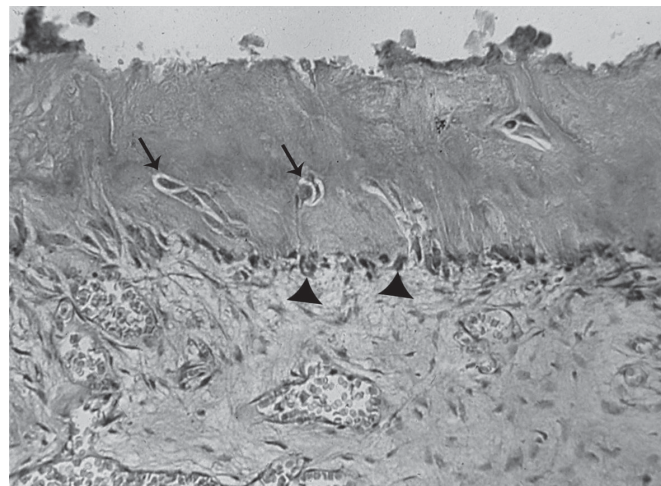


Fig. 5 - (group III; 30th day) - Hard tissue barrier with embedded cells (arrows). Newly-formed odontoblast-like cells organized in layer (arrowheads) and moderate deposition of dentin matrix. Hematoxylin-eosin, original magnification 125X.

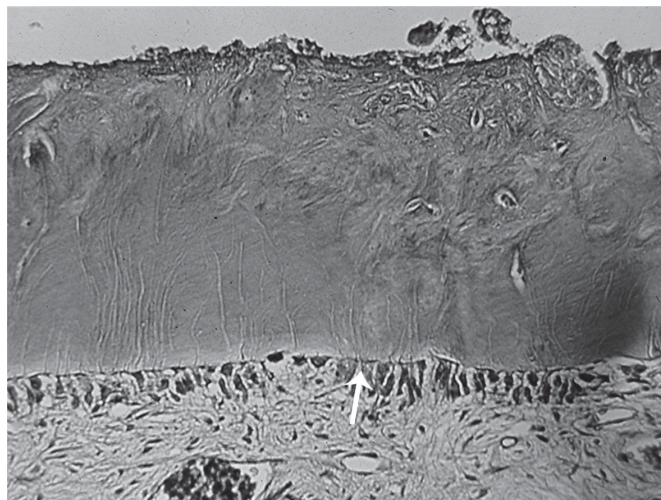

Fig. 6 - (group II; 60th day) - Presence of a large hard tissue barrier. Odontoblastic like cells are organized in layer (arrow) and absence of inflammatory characteristics in the connective tissue. Masson Trichrome stain, original magnification 125X.

calcification was observed in all groups. As a result, the dystrophic calcification associated with the dentin matrix gave rise to a noticeable hard barrier that remained between the capping material and the vital pulp tissue. It could also be seen a homogeneous monolayer of odontoblast-like cells underlying the tubular dentin matrix which was synthesized and deposited by these elongated pulp cells. Subjacent pulp tissue exhibited normal histological characteristics (Figure 6). One specimen of group I (control) and 1 specimen of group III presented mild persistent inflammatory pulp response associated with mild tissue disorganization and in these specimens stained bacteria along the outer third of the lateral cavity wall were observed.

The Kruskal Wallis statistical test applied to the attributed scores for the histological parameters showed that the period of evaluation had a significant influence ($p < 0.05$) on tissue disorganization and on hard tissue barrier formation in Group II. In the other groups (I and III) this test indicated

that tissue disorganization, and hard tissue barrier formation were also influenced significantly ($p < 0.05$) by the evaluation period and the inflammatory cell response.

There was greater inflammatory cell response ($p < 0.05$) in Groups I and III than in Group II on the 7th postoperative day. However, no significant difference was observed among the three groups on the 30th and on the 60th postoperative days ($p > 0.05$).

Discussion

Pulpotomy consists in cutting inflamed or infected coronary pulp and capping the remaining vital pulp tissue with a material that maintains its vitality¹⁸. This pulpal therapy has been strongly recommended for young permanent teeth, especially in clinical situations when a large pulp exposure is caused by decay or trauma or when the root is not completely formed^{7,12,14,16-18}. In the present study, the antiinflammatory effect of Otosporin® application before (10 min or 48 h) pulp capping with calcium hydroxide was investigated.

Calcium hydroxide has been the material of choice recommended for pulpotomy^{7,12,14,16-20}. The application of this material on pulpal wound causes superficial coagulation necrosis, which seems to participate in the pulpal healing process in association with hard barrier formation, although the calcium hydroxide mechanism of action is not yet well understood^{12-13,16-17,19-22}.

The dentin bridge may be a sign of healing or mild irritation, and the histological reaction to direct calcium hydroxide application onto pulpal tissue has been shown in several studies^{12,16-17,20,22}. In the present study, 7 days after application of this material, it could be seen the presence of odontoblast-like cells underlying the thick area of coagulation necrosis subjacent to pulp-capping agent, and only a mild inflammatory cell infiltrate. After 30 days, necrotic tissue in a dystrophic calcification process could be noted as well as the start of pulp repair with dentin bridge formation close to this tissue. Dentin bridge formation was apparently complete after 60 days of calcium hydroxide application, and the remaining pulp tissue presented normal histological characteristics.

The efficacy of calcium hydroxide as a pulp capping agent was reported to depend on its ability in releasing calcium and hydroxyl ions into the subjacent connective pulp tissue. The degree and speed of calcium and hydroxyl ion dissociation as well as the change in tissue pH values which the calcium hydroxide paste was applied to depend on the vehicle used to prepare the paste²³ (distilled water, in the present study). At the postoperative period of 7 days, a large zone of coagulation necrosis was observed in contact with pulp-capping material. This was probably due to the vehicle utilized, which allowed a highly alkaline pH since the moment that it was put in contact with the tissue. A previous study on the effects of pH on enzymatic activity in pulp tissue²⁴, have shown that the alkaline phosphatase activity, which is related to mineralization process, is increased by alkaline pH.

On the 30th postoperative day, the coagulation necrosis area presented calcification in its inner layer. A new odontoblastic layer was present, and newly formed dentin matrix was deposited nearby the pulpotomy area. This hard tissue barrier was larger on the 60th postoperative day. In all groups, it was characterized by the presence of dystrophic calcified tissue in the superficial layer and dentin deposition in the inner layer. These reactions are similar to those observed on healthy pulp tissue when direct calcium hydroxide application was made^{12,16-17,20,22}.

In a previous study¹³, on the other hand, an irregular dentin bridge formation was seen and no calcification or odontoblastic layer formation were observed on the 90th postoperative day. In a longer postoperative period (6 month), calcification and necrosis underneath the dentin bridge, mild hyperemia and mild chronic inflammation dominated by lymphocytes were observed, but no odontoblastic layer formation was noted¹³.

Franz et al.²⁵ in a study in humans and Yoshida et al.²⁶ in monkeys have also observed that the mineralized tissue barrier formed by pulps treated with calcium hydroxide consisted of a superficial osteodentin layer and a tubular dentin layer subjacent to that one, next to the pulp tissue. The thickness of this mineralized barrier increased in direct relationship to the length of the postoperative period²⁵ and its production tended to be made far from the capping material²⁶.

Corticosteroid can be used as a dressing agent in order to minimize pulp inflammation and consequently to provide relief of postoperative pain and sensibility^{1,4-5,8}. However, there is no consensus regarding the benefits of the use of this agent. The results of studies that employ corticosteroids as a cavity liner support that these medications are effective in reducing or preventing postoperative thermal sensitivity^{1,8,27}. On the other hand, when applied alone as direct pulp capping the results are poor³⁻⁵. Many investigators believe that the treatments are more successful when the products are used in combination with calcium hydroxide or when previous topical application is made before direct pulp capping^{3,28}.

Researchers have shown that application of corticosteroid/antibiotic association for short period of time was effective to control inflammation in the pulp tissue without determining changes in the healing process^{3,18}. Kakehashi et al.²⁷ have reported that 1-min application of prednisolone onto pulp tissue appeared not to alter the normal healing process in the absence of microorganisms, whereas appeared not to retard the pulpal degeneration process in the presence of bacterial infection. In the present study, the histological analysis showed no inhibition on blood vessels proliferation or on collagen deposition processes after corticosteroid/antibiotic dressing application for 10 min or 48 h.

The absence of significant difference among control and treated groups II and III (10 min or 48 h Otosporin® dressing, respectively) on different postoperative periods is in agreement with the observation that the corticosteroid/antibiotic association has no effect when applied on healthy dental pulp¹¹. Therefore, it can be suggested that previous pulp-capping application of a corticosteroid/antibiotic agent may be

unnecessary in routine clinical situations of accidental pulp exposure without inflammation like complicated crown fractures or complicated crown-root fractures in which the search for dental treatment is immediate or in cases of pulpotomies.

When pulp tissue is inflamed, Souza and Holland³ have reported that dressing with corticosteroid/antibiotic association for 48 h produced best results, presenting complete hard barrier deposition with absence of dispersion of inflammatory cells in the remaining tissue. Also in inflamed pulp tissue, Santini¹⁸ has observed that corticosteroid/antibiotic association maintained vitality for a longer period without interfering in the healing produced by the use of calcium hydroxide in pulpotomy made in young permanent human teeth.

In the present study, significant differences were observed for the scores of tissue disorganization and reparative dentine formation in the postoperative periods in all groups. However, significant difference was detected only between Group I (control) and Group III (48-h Otosporin[®] dressing) for inflammatory cell response. In these groups, the intensity of the inflammatory cell response was greater at 7 days than in the other periods. In Group II (10-min Otosporin[®] dressing), no significant difference was found in the inflammatory cell response scores during the course of the experiment. Sazak et al.²⁸ have also observed greater inflammation in Ledermix and calcium hydroxide association treated group when compared to calcium hydroxide alone on the 7th day.

Bacterial contamination is an important factor that may influence the response of injured pulp tissue and could be considered the primary cause of pulp death^{5,12,29}. After direct pulp-capping with calcium hydroxide, tissue healing and dentin bridge formation will be promoted by the pulp as long as bacterial microleakage is prevented¹². Bacteria can arise from the original carious lesion, from saliva, from the margins of the restoration by microleakage, and from the operator and instruments during the treatment^{5,12,29}. In the present study, presence of bacteria in the most superficial third of the lateral cavity walls was detected in only 6 specimens. From these, mild inflammatory response and tissue disorganization were observed in only 1 specimen of Group III on the 30th postoperative day. Since only noncarious teeth were used and the clinical procedures were performed under aseptic conditions, it may be assumed that bacteria probably reached the tooth-restoration interface through microleakage.

Within the limitations of present study, considering that the pulpotomy was performed in healthy teeth, it may be concluded that the use of a corticosteroid/antibiotic dressing before remaining tissue protection with calcium hydroxide had no influence on pulp tissue healing.

References

- Dachi SF, Ross A, Stigers RW. Effects of prednisolone on the thermal sensitivity and pulp reactions of amalgam restored teeth. *J Am Dent Assoc.* 1964; 69: 565-71.
- Van Hassel HJ, McHugh JW. Effect of prednisolone on intrapulpal pressure [abstract 499]. *J Dent Res.* 1972; 51: 172.
- Souza V, Holland R. Treatment of the inflamed dental pulp. *Aust Dent J.* 1974; 19: 191-6.
- Paterson RC. Corticosteroids and the exposed pulp. *Br Dent J.* 1976; 140: 174-7.
- Paterson RC. Bacterial contamination and the exposed pulp. *Br Dent J.* 1976; 140: 231-6.
- Holland R, Okabe JA, Souza V, Saliba O. Diffusion of corticosteroid-antibiotic solutions through human dentine. *Rev Odontol UNESP.* 1991; 20: 17-23.
- Qudeimat MA, Barrieshi-Nusair KM, Owais AI. Calcium hydroxide vs mineral trioxide aggregates for partial pulpotomy of permanent molars with deep caries. *Eur Arch Paediatr Dent.* 2007; 8: 99-104.
- Fry AE, Watkins RF, Phatak NM. Topical use of corticosteroids for the relief of pain sensitivity of dentine and pulp. *Oral Surg Oral Med Oral Pathol.* 1960; 13: 594-7.
- Mosteller JH. Use of prednisolone in the elimination of postoperative thermal sensitivity: a clinical study. *J Prosthet Dent.* 1962; 12: 1176-9.
- Schroeder A. Combination of antibiotics and cortisone in the treatment of root canals. *Rev Belge Med Dent.* 1965; 20: 291-8.
- Uitto VJ, Antila R, Ranta R. Effects of topical glucocorticoid medication on collagen biosynthesis in the dental pulp. *Acta Odontol Scand.* 1975; 33: 287-98.
- Sübay RK, Suzuki S, Suzuki S, Kaya H, Cox CF. Human pulp response after partial pulpotomy with two calcium hydroxide products. *Oral Surg Oral Med Oral Pathol Oral Radiol Endod.* 1995; 80: 330-7.
- Aeinehchi M, Eslami B, Ghanbari M, Saffar AS. Mineral trioxide aggregate (MTA) and calcium hydroxide as pulp-capping agents in human teeth: a preliminary report. *Int Endod J.* 2003; 36: 225-31.
- El-Meligy OA, Avery DR. Comparison of mineral trioxide aggregate and calcium hydroxide as pulpotomy agents in young permanent teeth (apexogenesis). *Pediatr Dent.* 2006; 28: 399-404.
- Pradhan DP, Chawla HS, Gauba K, Goyal A. Comparative evaluation of endodontic management of teeth with unformed apices with mineral trioxide aggregate and calcium hydroxide. *J Dent Child.* 2006; 7: 79-85.
- Hebling J, Giro EMA, Costa CAS. Biocompatibility of an adhesive system applied to exposed human dental pulp. *J Endod.* 1999; 25: 676-82.
- de Albuquerque DS, Gominho LF, Dos Santos RA. Histologic evaluation of pulpotomy performed with ethyl-cyanocrylate and calcium hydroxide. *Braz Oral Res.* 2006; 20: 226-30.
- Santini A. Assessment of the pulpotomy technique in human first permanent mandibular molars. *Br Dent J.* 1983; 155: 151-4.
- Heys DR, Cox CF, Heys RJ, Avery JK. Histological considerations of direct pulp capping agents. *J Dent Res.* 1981; 60: 1371-9.
- Schroeder U. Effects of calcium hydroxide-containing pulp capping agent on pulp cell migration, proliferation and differentiation. *J Dent Res.* 1985; 64: 541-8.
- Stanley HR, Lundy T. Dycal therapy for pulp exposures. *Oral Surg Oral Med Oral Pathol.* 1972; 34: 818-27.
- Mjor IA, Dahl E, Cox CF. Healing of pulp exposures: an ultrastructural study. *J Oral Pathol Med.* 1991; 20: 496-501.
- de Andrade Ferreira FB, Silva e Souza PDEA, Do Vale MS, De Moraes IG, Granjeiro JM. Evaluation of pH levels and calcium ion release in various calcium hydroxide endodontic dressings. *Oral Surg Oral Med Oral Pathol Oral Radiol Endod.* 2004; 97: 388-92.
- Gordon TM, Ranly DM, Boyan BD. The effect of calcium hydroxide on bovine pulp tissue: variations in pH and calcium concentration. *J Endod.* 1985; 11: 156-60.
- Franz FE, Holz J, Baume LJ. Ultrastructure (SEM) of dentin bridging in the human dental pulp. *J Biol Buccale.* 1984; 12: 239-46.
- Yoshida K, Yoshida N, Iwaku M. Histological observations of hard tissue barrier formation in amputated dental pulp capped with alpha-tricalcium phosphate containing calcium hydroxide. *Endod Dent Traumatol.* 1994; 10: 113-20.

27. Kakehashi S, Stanley HR, Fitzgerald R. The exposed germ-free pulp: effects of topical corticosteroid medication and restoration. *Oral Surg Oral Med Oral Pathol.* 1969; 27: 60-7.
28. Sazak H, Günday M, Alatli C. Effect of calcium hydroxide and combinations of Ledermix and calcium hydroxide on inflamed pulp in dog teeth. *J Endod.* 1996; 22: 447-9.
29. Cox CF, Bergenholtz G, Heys DR, Syed SA, Fitzgerald M, Heys RJ. Pulp capping of dental pulp mechanically exposed to oral microflora: a 1-2 year observation of wound healing in the monkey. *J Oral Pathol.* 1985; 14: 156-68.