

Smile analysis and photoshop smile design technique

Prof. Edward A. McLaren & Lee Culp¹

Introduction: Smile analysis and aesthetic design

Dental facial aesthetics can be defined in three ways.

Traditionally, dental and facial aesthetics have been defined in terms of macro- and micro-elements. Macro-aesthetics encompasses the interrelationships between the face, lips, gingiva, and teeth and the perception that these relationships are pleasing. Micro-aesthetics involves the aesthetics of an individual tooth and the perception that the colour and form are pleasing.

Historically, accepted smile design concepts and smile parameters have helped to design aesthetic treatments. These specific measurements of form, colour, and tooth/aesthetic elements aid in transferring smile design information between the dentist, ceramist, and patient. Aesthetics in dentistry can encompass a broad area - known as the aesthetic zone.¹

Rufenacht delineated smile analysis into facial aesthetics, dentofacial aesthetics, and dental aesthetics, encompassing the macro- and micro-elements described in the first definition above.² Further classification identifies five levels of aesthetics: facial, orofacial, oral, dentogingival, and dental (Table 1).^{1,3}

Initiating smile analysis: Evaluating facial and orofacial aesthetics

The smile analysis/design process begins at the macro level, examining the patient's face first, progressing to an evaluation of the individual teeth, and finally moving to material selection considerations. Multiple photographic views (e.g., facial and sagittal) facilitate this analysis.

At the macro level, facial elements are evaluated for form and balance, with an emphasis on how they may be affected by dental treatment.^{3,4} During the macro-analysis, the balance of the facial thirds is examined (Fig. 1). If something appears unbalanced in any one of those zones, the face and/or smile will appear unaesthetic.

Such evaluations help determine the extent and type of treatment necessary to affect

¹ Prof. Edward A. McLaren, DDS, is the director of the University of California, Los Angeles Center for Esthetic Dentistry in California, US. He maintains a private practice in Los Angeles.

² Lee Culp, CDT, is an adjunct faculty member at the University of North Carolina at Chapel Hill School of Dentistry in the US and an accredited member of the American Academy of Cosmetic Dentistry. He practices in Dublin, California, and Raleigh, North Carolina.



Figure 1: Three altered views of the same patient enable analysis of what can be accomplished to enhance facial and smile aesthetics.

Table 1: Components of smile analysis and aesthetic design

Facial aesthetics	Total facial form and balance
Orofacial aesthetics	Maxillomandibular relationship to the face and the dental midline relationship to the face pertaining to the teeth, mouth and gingiva
Oral aesthetics	Labial, dental, gingival; the relationships of the lips to the arches, gingiva, and teeth
Dentogingival aesthetics	Relationship of the gingiva to the teeth collectively and individually
Dental aesthetics	Macro- and micro-aesthetics, both inter- and intra-tooth



Figure 2: Sagittal views best demonstrate which specialists should be involved in treatment, whether orthodontists or maxillofacial surgeons, to best aesthetically alter the facial aesthetics.

the aesthetic changes desired. Depending on the complexity and uniqueness of a given case, orthodontics could be considered when restorative treatment alone would not produce the desired results (Fig. 2), such as when facial height is an issue and the lower third is affected. In other cases - but not all - restorative treatment could alter the vertical dimension of occlusion to open the bite and enhance aesthetics when a patient presents with relatively even facial thirds (Fig. 3).

Evaluating oral aesthetics

The dentolabial gingival relationship, which is considered oral aesthetics, has traditionally been the starting point for treatment planning. This process begins by determining the ideal maxillary incisal edge placement (Fig. 4). This is accomplished by understanding the incisal edge position relative to several different landmarks. The following questions can be used to determine the ideal incisal edge position:

- Where in the face should the maxillary incisal edges be placed?
- What is the proper tooth display, both statically and dynamically?

- What is the proper intra- and inter-tooth relationship (e.g., length and size of teeth, arch form)?
- Can the ideal position be achieved with restorative dentistry alone, or is orthodontics needed?



Figure 3: Drawing a line along the glabella, subnasale, and pogonion enables a quick evaluation of aesthetics without the need for radiographs to determine alignment of ideal facial elements.

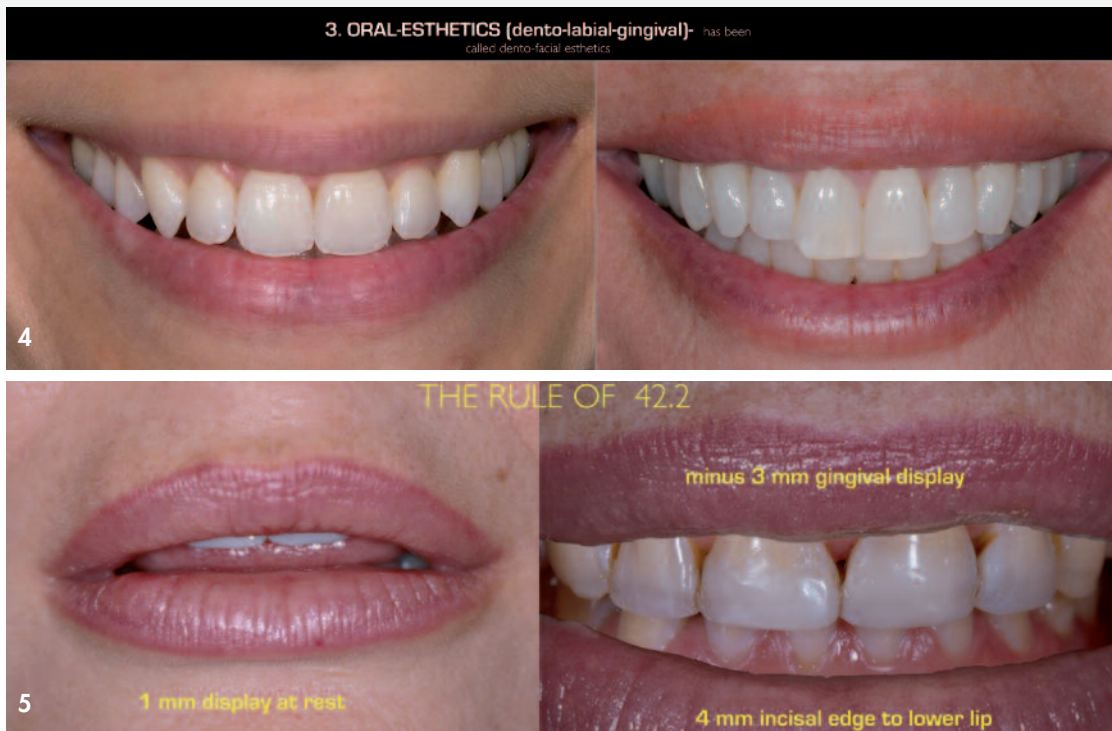

Figure 4: Evaluating the maxillary incisal edge position is the starting point for establishing oral aesthetics. Figure 5: According to the 4.2.2 rule, this patient's smile is deficient in aesthetic elements, having only 1 mm of tooth display at rest (left), minus 3 mm of gingival display, and 4 mm of space between the incisal edge and the lower lip (right).

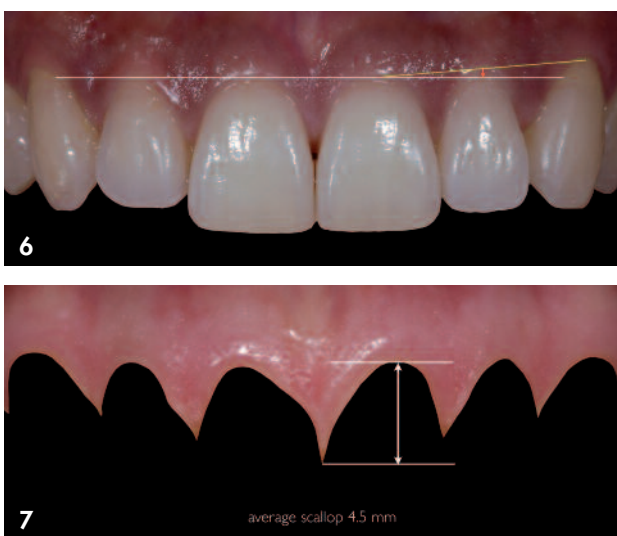


Figure 6: Gingival symmetry in relation to the central incisors, lateral incisors and canines is essential to aesthetics. Optimal aesthetics is achieved when the gingival line is relatively horizontal and symmetrical on both sides of the midline in relation to the central incisors and lateral incisors. Figure 7: The aesthetic ideal from the gingival scallop to the tip of the papilla is 4–5 mm.

In order to facilitate smile evaluation based on these landmarks, the rule of 4.2.2 - which refers to the amount of maxillary central display when the lips are at rest, the amount of gingival tissue revealed, and the proximity of the incisal line to the lower lip - is helpful (Fig. 5). At a time when patients perceive fuller and brighter smiles as most aesthetic, 4mm of maxillary central incisor display while the lips are at rest may be ideal.^{2,5} In an aesthetic smile, seeing no more than 2mm of gingiva when the patient is fully smiling is ideal.⁶ Finally, the incisal line should come very close to and almost touch the lower lip, being no more than 2mm away.² These guidelines are somewhat subjective and should be used as a starting point for determining proper incisal edge position.

Dentogingival aesthetics

Gingival margin placement and the scalloped shape, in particular, are well discussed in the literature. As gingival heights are measured, heights relative to the central incisor, lateral incisor, and canine in an up/down/up relationship are considered aesthetic (Fig. 6). However, this may create a false perception that the lateral gingival line is incisal to

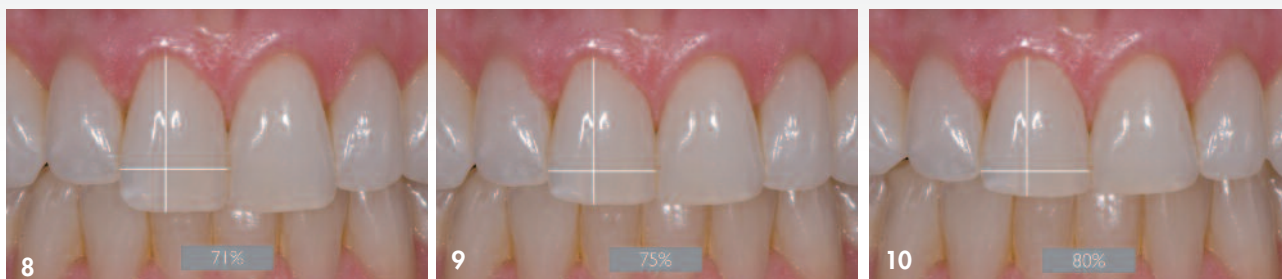

Figure 8-10: Acceptable width-to-length ratios fall between 70% and 85%, with the ideal range between 80% and 85%.

the central incisor. Rather, in most aesthetic tooth relationships, the gingival line of the four incisors is approximately the same line (Fig. 6), with the lateral incisor perhaps being slightly incisal.⁷ The gingival line should be relatively parallel to the horizon for the central incisors and the lateral incisors and symmetric on each side of the midline.^{2,8} The gingival contours (i.e., gingival scallop) should follow a radiating arch similar to the incisal line. The gingival scallop shapes the teeth and should be between 4mm and 5mm (Fig. 7).⁹

Related to normal gingival form is midline placement. Although usually the first issue addressed in smile design, it

is not as significant as tooth form, gingival form, tooth shape, or smile line.

Several rules can be applied when considering modifying the midline to create an aesthetic smile design:

- The midline only should be moved to establish an aesthetic intra- and inter-tooth relationship, with the two central incisors being most important.
- The midline only should be moved restoratively up to the root of the adjacent tooth. If the midline is within 4mm of the centre of the face, it will be aesthetically pleasing.
- The midline should be vertical when the head is in the postural rest position.

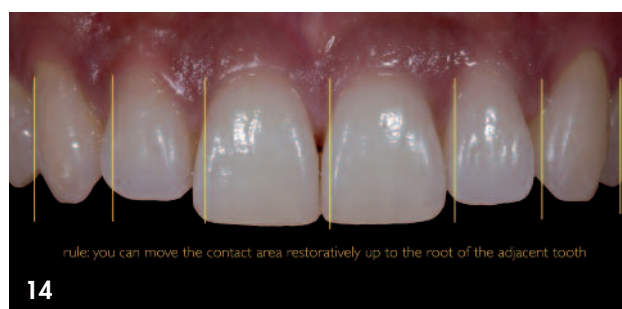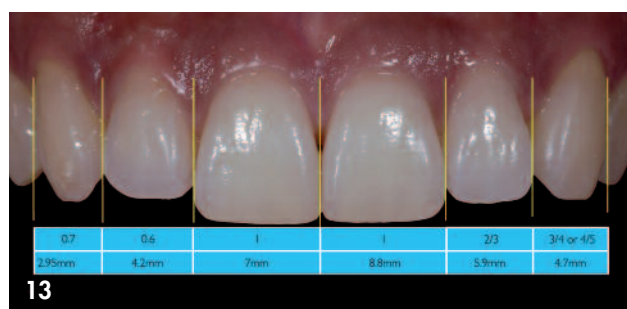
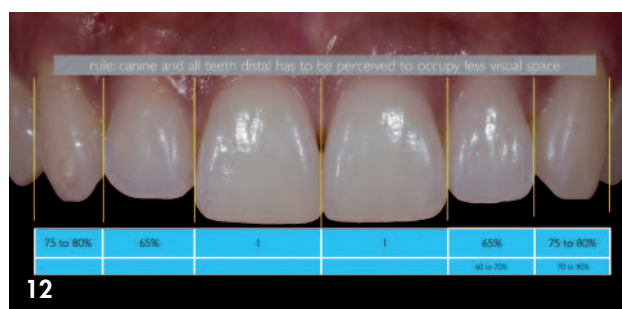

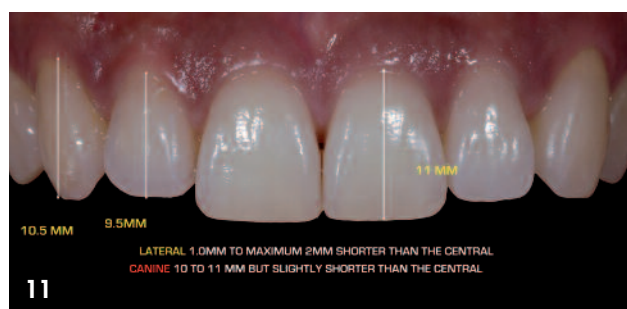
Figure 11: An acceptable starting point for central incisors is 11 mm in length, with lateral incisors 1–2mm shorter than the central incisors, and canines 0.5–1 mm shorter than the central incisors for an aesthetic smile display. Figure 12: The canines and other teeth distally located are visually perceived as occupying less space in an aesthetically pleasing smile. Figure 13: A general rule for achieving proportionate smile design is that lateral incisors should measure two-thirds of the central incisors and canines four-fifths of the lateral incisors. Figure 14: If feasible, the contact areas can be restoratively moved up to the root of the adjacent tooth.

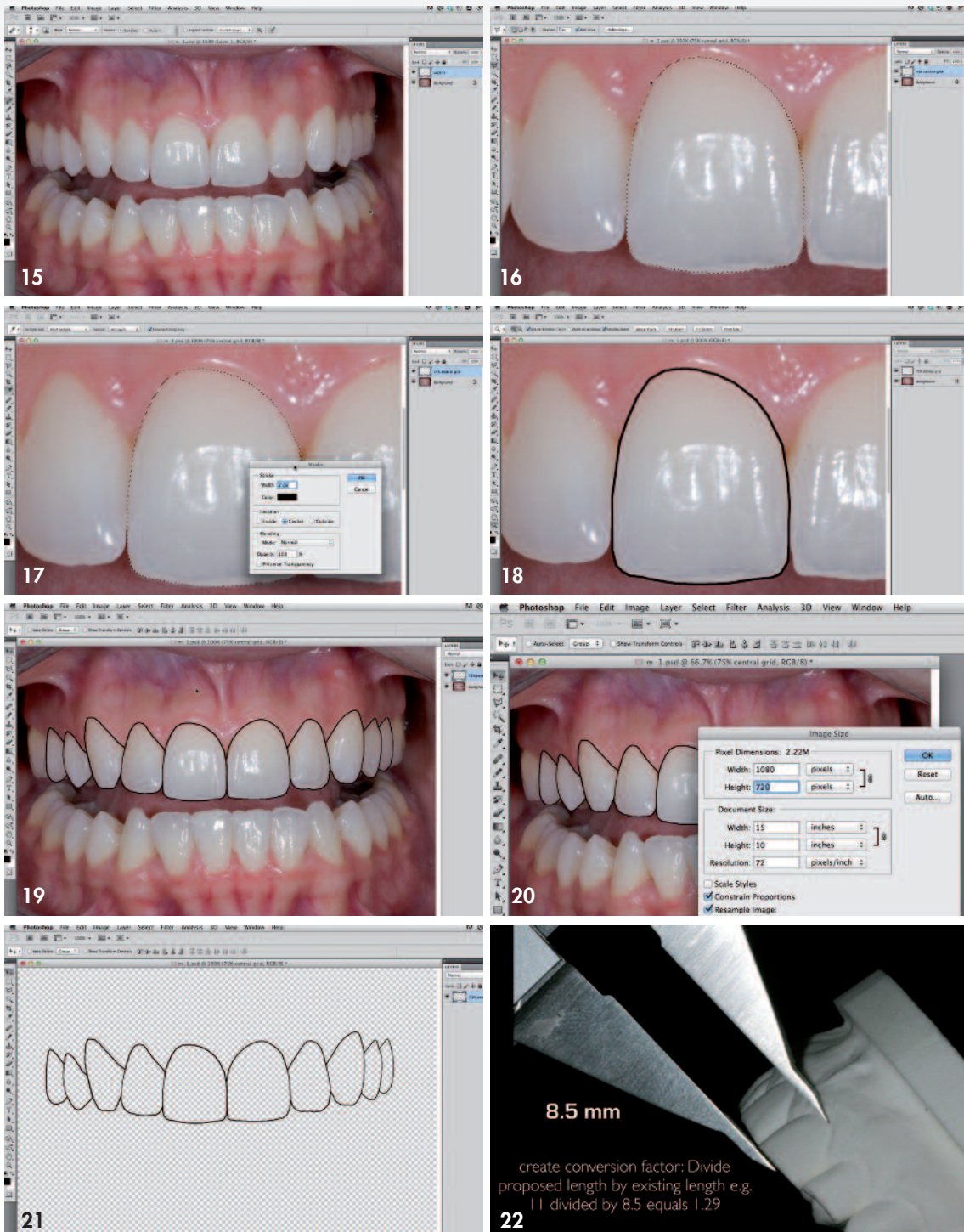


Figure 15: Photoshop provides an effective and inexpensive way to design a digital smile with proper patient input. To start creating custom tooth grids, open an image of an attractive smile in Photoshop and create a separate transparent layer. Figure 16: The polygonal lasso tool is an effective way to select the teeth. Figure 17: Click "edit > stroke," then use a two-pixel stroke line (with colour set to black) to trace your selection. Make sure the transparent layer is the active working layer. Figure 18: Image of the central incisor with a two-pixel black stroke (tracing). Figure 19: Image of the teeth traced up to the second premolar to create a tooth grid. Figure 20: Size the image in Photoshop. Figure 21: Save the grid as a .png or .psd file type and name it appropriately. Create other dimension grids using the same technique. Figure 22: To determine the digital tooth size, a conversion factor is created by dividing the proposed length by the existing length of the tooth.

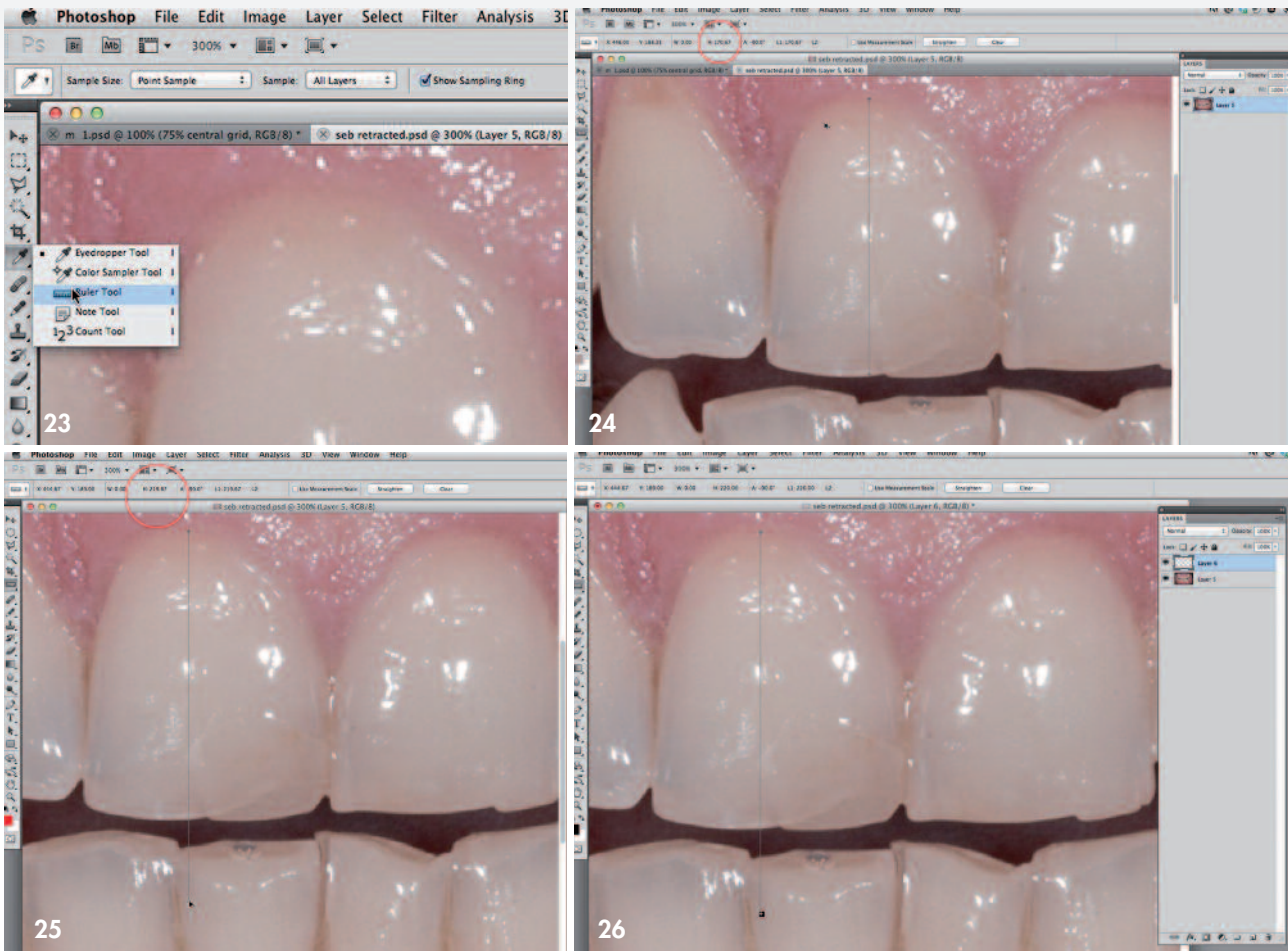


Figure 23: Select the ruler tool in Photoshop. Figure 24: Measure the digital length of the central incisor using the ruler tool. Figure 25: Measure the new digital length using the conversion factor created earlier. Figure 26: Create a new transparent layer and mark the new proposed length with the pencil tool.

Evaluating dental aesthetics

Part of evaluating dental aesthetics for smile design is choosing tooth shapes for patients based on their facial characteristics (e.g., long and dolichocephalic, or squarish and brachycephalic). When patients present with a longer face, a more rectangular tooth within the aesthetic range is appropriate. For someone with a square face, a tooth with an 80% width-to-length ratio would be more appropriate. The width-to-length ratio most often discussed in the literature is between 75% and 80%, but aesthetic smiles could demonstrate ratios between 70% and 75% or between 80% and 85% (Figs. 8–10).¹

The length of teeth also affects aesthetics. Maxillary central incisors average between 10mm and 11mm in length. According to Magne, the average length of an unworn maxillary central to the cemento-enamel junction is slightly

over 11mm.¹⁰ The aesthetic zone for central incisor length, according to the authors, is between 10.5mm and 12mm, with 11mm being a good starting point. Lateral incisors are between 1mm and a maximum of 2mm shorter than the central incisors, with the canines slightly shorter than the central incisors by between 0.5mm and 1mm (Fig. 11).

The inter-tooth relationship, or arch form, involves the golden proportion and position of tooth width.

Although it is a good beginning, it does not reflect natural tooth proportions. Natural portions demonstrate a lateral incisor between 60% and 70% of the width of the central incisor, and this is larger than the golden proportion.¹¹ However, a rule guiding proportions is that the canine and all teeth distal should be perceived to occupy less visual space (Fig. 12). Another rule to help maintain proportions throughout the arch is 1-2-3-4-5; the lateral incisor is two-thirds of the central incisor and

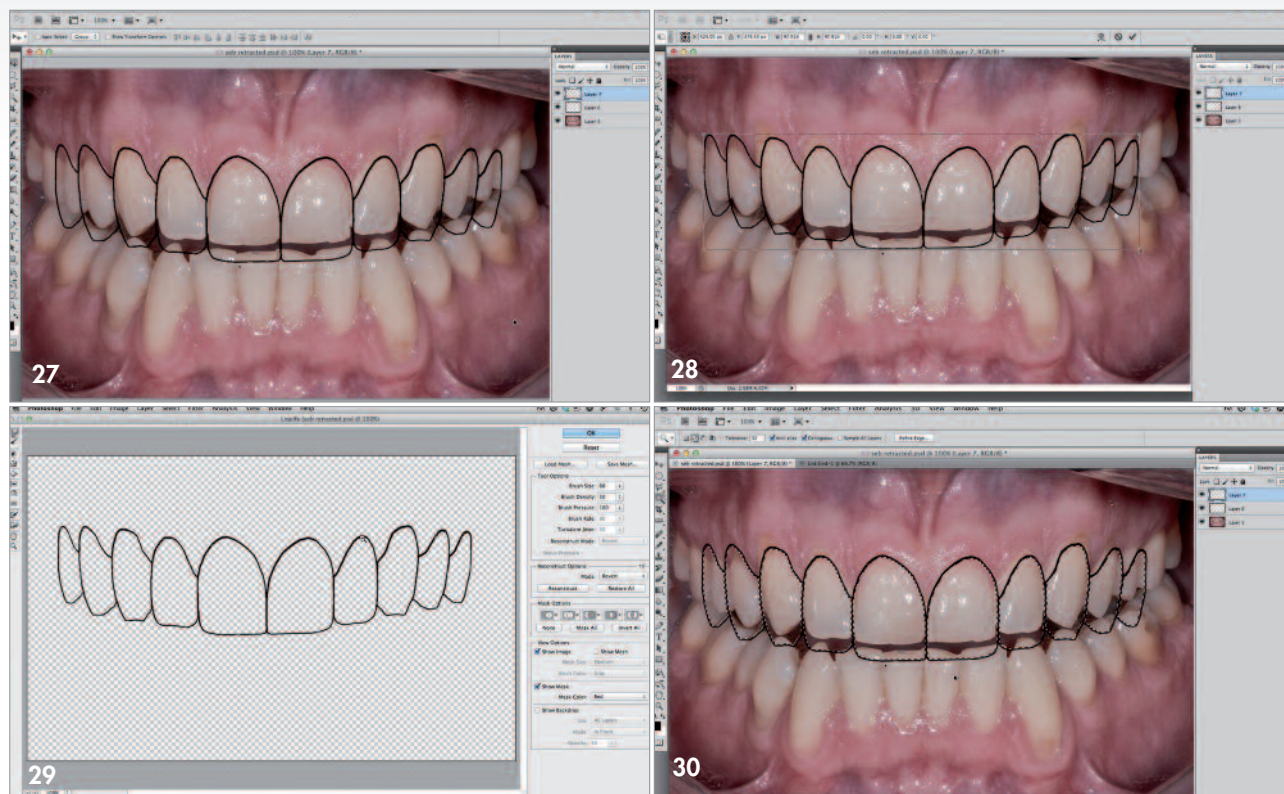


Figure 27: Open the image of the chosen tooth grid in Photoshop and drag the grid on to the image of teeth to be smile designed. This will create a new layer in the image to be smile designed. Figure 28: Adjust the grid as required while maintaining proper proportions by using the free transform tool from the edit menu. Figure 29: Modify the grid shape as necessary using the liquify tool. Figure 30: Select all of the teeth in the grid by activating the magic wand selection tool and then clicking on each tooth with the grid layer activated (highlighted) in the layers palette.

the canine is four-fifths of the lateral incisor, with some latitude within those spaces (Fig. 13). Finally, contact areas can be moved restoratively up to the root of the adjacent tooth.

Beyond that, orthodontics is required (Fig. 14).

Creating a digital smile designed in Photoshop

Although there are digital smile design services available to dentists for a fee, it is possible to use Photoshop CS5 software (Adobe Systems) to create and demonstrate for patients the proposed smile design treatments. It starts by creating tooth grids—predesigned tooth templates in different width-to-length ratios (e.g., 75% central, 80% central) that can be incorporated into a custom smile design based on patient characteristics. You can create as many different tooth grids as you like with different tooth proportions in the aesthetic zone. Once completed, you will not have to do this step again, since you will save the created tooth grids and use them to create a new desired outline form for the desired teeth.

Follow these recommended steps:

- To begin creating a tooth grid, use a cheek-retracted image of an attractive smile as a basis (e.g., one with a 75% width-to-length ratio). Open the image in Photoshop and create a new clear transparent layer on top of the teeth (Fig. 15). This transparent layer will enable the image to be outlined without the work being embedded into the image.
- Name the layer appropriately and, when prompted to identify your choice of fill, choose “no fill,” since the layer will be transparent, except for the tracing of the tooth grid.
- To begin tracing the tooth grid, activate a selection tool, move to the tool palette, and select either the polygonal lasso tool or the magnetic lasso tool. In the authors’ opinion, the polygonal works best. Once activated, zoom in (Fig. 16) and trace the teeth with the lasso tool.
- To create a pencil outline of the tooth, with the transparent layer active, click on the edit menu in the menu bar; in the edit drop-down menu, select “stroke”; choose black

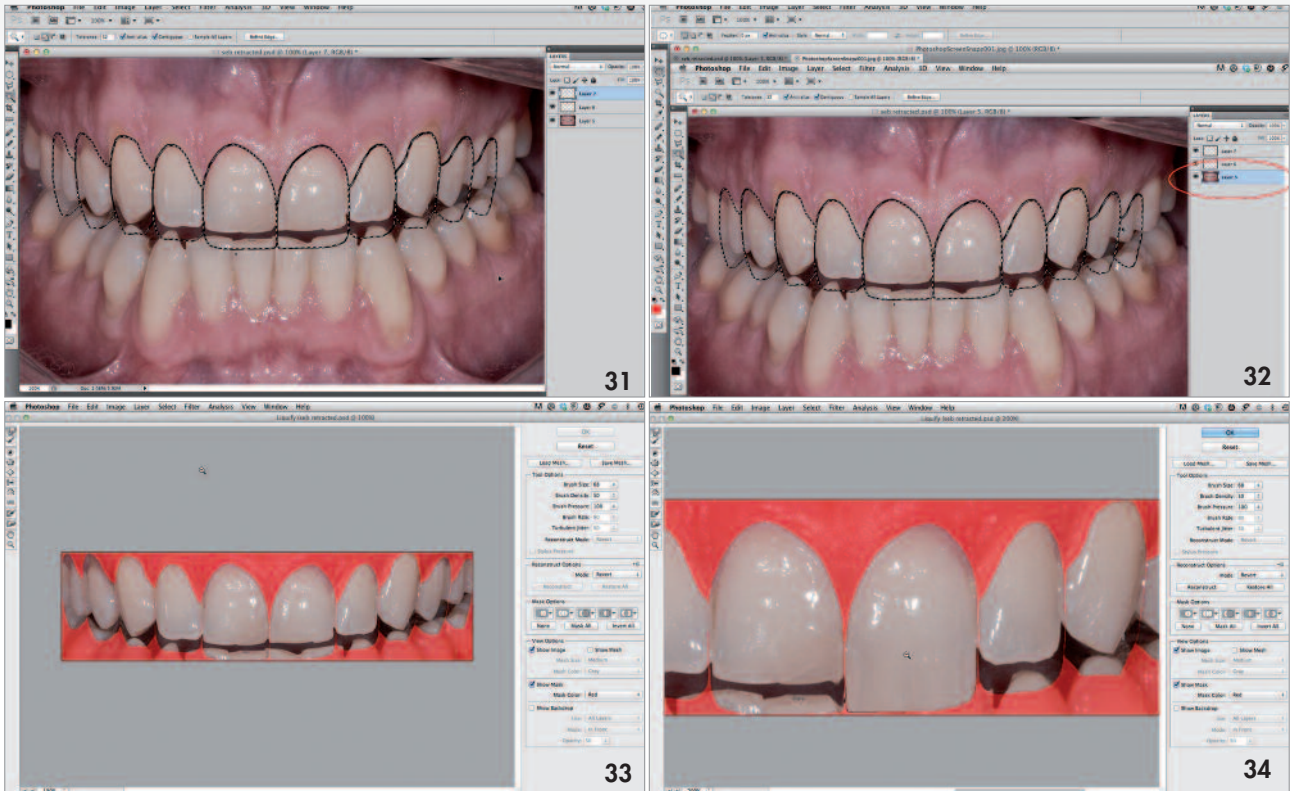


Figure 31: Use the selection modify tool to expand the selection to better fit the grid shape. Figure 32: Activate the layer of the teeth by clicking on it. Blue-coloured layers are active. Figure 33: With the layer of the teeth highlighted, choose “liquify”; a new window will appear with a red background called a “mask”. Figure 34: Shape one tooth at a time as needed by selecting “wand”.

for colour, and select a two-pixel stroke pencil line (Fig. 17), which will create a perfect tracing of your selection. Click “OK” to stroke the selection. Select (trace with the lasso selection tool) one tooth at a time and then stroke it (Fig. 18). Select and stroke (trace) the teeth up to the second premolar (the first molar is acceptable; Fig. 19).

- The image should be sized now for easy future use in a smile design. In the authors’ experience, it is best to adjust the size of the image to a height of 720 pixels (Fig. 20) by opening up the image size menu and selecting 720 pixels for the height. The width will adjust proportionately.
- At this time, the tooth grid tracing can be saved, without the image of the teeth, by double-clicking on the layer of the tooth image. A dialog box reading “new layer” will appear; click “OK.” This process unlocks the layer of the teeth so it can be removed. Drag the layer of the teeth to the trash, leaving only the layer with the tracing of the teeth (Fig. 21). In the file menu, click “save as” and choose “.png” or “.psd” (Photoshop) as the file type. This will preserve the transparency. You do not want to save it as a JPEG, since this would create a white background

around the tracing. Name the file appropriately (e.g., 75% W/L central).

- By tracing several patients’ teeth that have tooth size and proportion in the aesthetic zone and saving them, you can create a library of tooth grids to custom design new teeth for your patients who require smile designs.

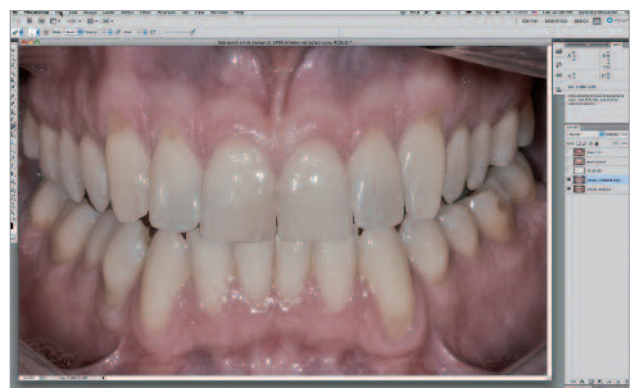


Figure 35: Once all of the teeth have been shaped, use the liquify tool.

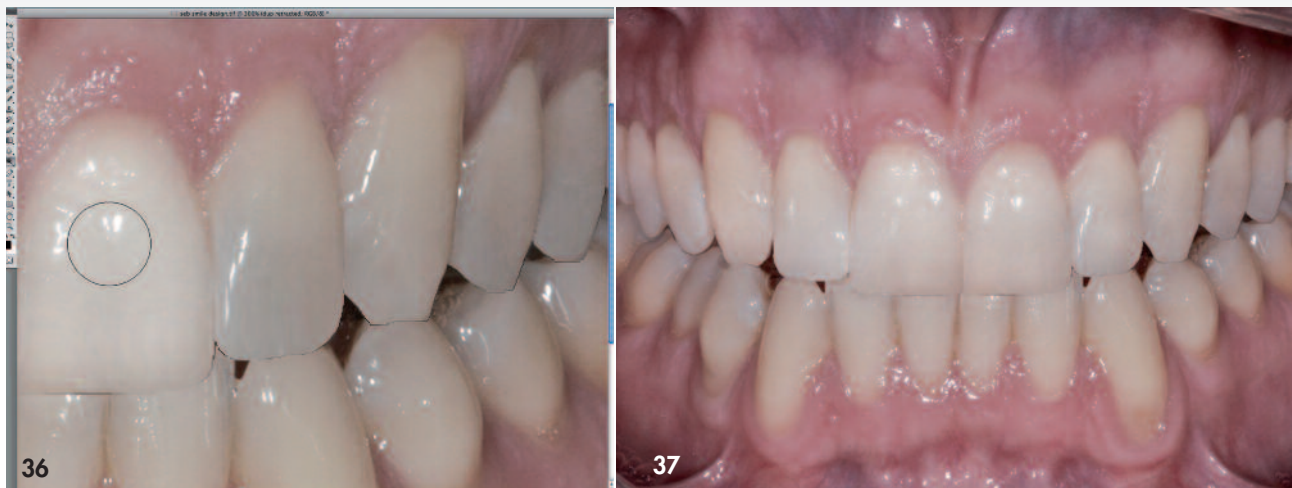

Figure 36: Tooth brightness is adjusted using commands from the dodge tool menu or image adjustments menu. Figure 37: Image of all the teeth whitened with the dodge tool.

The Photoshop smile design technique

The Photoshop Smile Design (PSD) technique can be done on any image, and images can be combined to show the full face or the lower third with lips on or lips off. This article demonstrates how to perform the technique on the cheek-retracted view.

The first step in the PSD technique is to create a digital conversion of the actual tooth length and width, and then digitally determine the proposed new length and proportion of the teeth.

Determining digital tooth size

To determine digital tooth size, follow these steps:

- Create a conversion factor by dividing the proposed length (developed from the smile analysis) by the existing length of the tooth.
- The patient's tooth can be measured in the mouth or on the cast (Fig. 22). If the length measures 8.5mm but needs to be at 11 mm for an aesthetic smile, divide 11 by 8.5. The conversion factor equals 1.29, a 29% digital increase lengthwise.
- Open the full-arch cheek-retracted view in Photoshop, and zoom in on the central incisor.
- Select the eyedropper palette. A new menu will appear. Select the ruler tool (Fig. 23).
- Click and drag the ruler tool from the top to the bottom of the tooth to generate a vertical number, in this case 170 pixels (Fig. 24). Multiply the number of pixels by the conversion factor. In this case, $170 \times 1.29 = 219$ pixels; 219 pixels is digitally equivalent to 11 mm (Fig. 25).

Determine the digital tooth width using the same formula.

- Create a new layer, leave it transparent, and mark the measurement with the pencil tool (Fig. 26).

Applying a new proposed tooth form

Next, follow these steps:

- After performing the smile analysis and digital measurements, choose a custom tooth grid appropriate for the patient. Select a tooth grid based on the width-to-length ratio of the planned teeth (e.g., 80/70/90 or 80/65/80). Open the image of the chosen tooth grid in Photoshop and drag the grid on to the image of teeth to be smile designed (Fig. 27).
- If the shape or length is deemed inappropriate, press the command button (control button for PCs) and "z" to delete and select a suitable choice.
- Depending on the original image size, the tooth grid may be proportionally too big or too small. To enlarge or shrink the tooth grid created (with the layer activated), press command (or control) and "t" to bring up the free transform function. While holding the shift key (holding the shift key allows you to transform the object proportionally), click and drag a corner left or right to expand or contract the custom tooth grid.
- Adjust the size of the grid so that the outlines of the central incisors have the new proposed length. Move the grid as necessary using the move tool so that the incisal edge of the tooth grid lines up with the new proposed length (Fig. 28).
- Areas of the grid can be individually altered using the liquify tool (Fig. 29).

Digitally creating new aesthetic teeth

Next, follow these suggested steps:

- With the new tooth grid layer and the magic wand tool both activated, click on each tooth to select all of the teeth in the grid (Fig. 30).
- Expand the selection by two pixels in the expand menu; click "select > modify > expand" (Fig. 31). Note that the selection better approximates the grid. You can expand the selection or contract as necessary using the same menu.
- Activate the layer of the teeth (cheek-retracted view) by clicking on it (Fig. 32).
- Next, activate the liquify filter (you will see a red mask around the shapes of the proposed teeth). The mask creates a digital limit that the teeth cannot be altered beyond. This is similar to creating a mask with tape for painting a shape (Fig. 33).
- Use the forward warp tool by clicking on an area of the existing tooth and dragging to mold/shape the tooth into the shape of the new proposed outline form (Fig. 34).

Repeat this for each tooth. If you make a mistake or do not like something, click command (or control) and "z" to go back to the previous edit (Fig. 35).

Adjusting tooth brightness

The following steps are recommended next:

- Select the whitening tool (dodge tool) to brighten the teeth. In the dodge tool palette, click on "midtone" and set the exposure to approximately 20%. Click on the areas of the tooth you want brightened (Figs. 36 & 37).
- Alternatively, with the teeth selected, you can use the brightness adjustment in the brightness/contrast menu; click "image > adjustments > brightness/ contrast".

Performing the changes on only one side of the mouth

allows the patient to compare the new smile design to his/her original teeth before agreeing to treatment.

Create a copy

To save the information you have created for presentation to the patient, follow these tips:

- Go to "file" and select "save as."
- When the menu appears, click on the "copy" box.
- Name the file at that step.
- Save it as a JPEG file type.
- Designate where you want it saved.
- Click "save."

A file of the current state of the image will be created in the designated area. You can now continue working on the image and save again at any point you want.

Conclusion

Knowledge of smile design, coupled with new and innovative dental technologies, allows dentists to diagnose, plan, create, and deliver aesthetically pleasing new smiles. Simultaneously, digital dentistry is enabling dentists to provide what patients demand: quick, comfortable, and predictable dental restorations that satisfy their aesthetic needs.

Editorial note: A complete list of references is available from the publisher.

This article was originally published in the Journal of Cosmetic Dentistry, spring issue, No 1/2013, Vol. 29, and the Clinical Masters Magazine No 1/2015.

Reprinted with permission by Cad/Cam, 2/2015