

Nonretentive Bonded Ceramic Partial Crowns: Concept and Simplified Protocol for Long-lasting Dental Restorations

Gianfranco Politano^a / Bart Van Meerbeek^b / Marleen Peumans^c

Purpose: Adhesively luted partial ceramic crowns have been documented to be clinically more durable than direct composite restorations when minimally invasively restoring large defects (replacing two cusps or more) in posterior teeth. The clinical longevity of such restorations is largely determined by the tooth-preparation design, material selection and adhesive luting procedure. The most frequently recorded failure in medium- to long-term clinical trials is fracture of the restoration. The clinical protocol of adhesively luted partial ceramic crowns can be optimized by taking the etiology of these restoration fractures into account. In this article, a simplified nonretentive bonded ceramic partial crown concept is presented that aims to achieve an adhesively luted ceramic restoration – composite cement – residual tooth structure biomechanical unit that maximally resists functional aging. Therefore, the three primary components of the bonded restoration-cement-tooth complex must function in synergy.

Methods, Results and Discussion: The clinical protocol starts with a tooth preparation designed to optimally absorb chewing stress. A stable, internally rounded and gently sloping tooth-preparation design with all outer margins inclined towards the tooth center assures a favorable and homogenous stress distribution with low cyclic fatigue subjected to the adhesive interface. This preparation form additionally enables the dental technician to fabricate a well-seating and -fitting ceramic restoration of uniform thickness. As restoration material, monolithic lithium-disilicate glass ceramic is sufficiently strong for the partial crown indication and preferred in order to decrease the fracture risk. Clinically essential for a long-lasting restoration is the optimal bond that can be obtained by combined micromechanical interlocking and chemical bonding of composite cement to hydrofluoric acid-etched and silanized glass ceramic.

Conclusion: The clinical effectiveness of this nonretentive bonded ceramic partial crown concept is confirmed by the overall high success rate as well as the very low fracture and debonding rate, as was recorded in long-term clinical trials.

Keywords: overlay, onlay, tooth preparation, glass ceramic, indirect restoration.

*J Adhes Dent 2018; 20: 495–510.
doi: 10.3290/j.jad.a41630*

Submitted for publication: 26.10.18; accepted for publication: 19.11.18

Restoring posterior teeth exhibiting large defects (replacing two cusps or more) with directly bonded restorative composite is possible, but can be very challenging for

the dentist, in particular in busy clinical practices where treatment time should be as short as possible.⁶⁹ Upon a detailed biomechanical analysis of the remaining tooth structure, the tooth should be prepared minimally invasively, preserving as much sound tissue as possible, while removing any tooth parts with doubtful stability. In this sense, thin unsupported cusps must be reduced, as this will increase the durability of the restoration. The most difficult steps in the fabrication of large direct posterior composite restorations are the creation of a correct form with good occlusal anatomy as well as of well-contoured proximal surfaces with strong and correctly positioned contact points with the neighboring teeth. A posterior tooth restored in this direct composite workflow can function quite well in the medium term (ca 3-5 years).^{27,54,85} Bruxism and high caries risk seriously affect the durability of extensive composite restorations.^{68,92} Bonded indirect ceramic partial

^a Dentist in Private Practice, Rome, Italy. Developed the concept, constructed the figures, proofread the manuscript.

^b Full Professor; KU Leuven (University of Leuven), Department of Oral Health Sciences, BIOMAT & UZ Leuven (University Hospitals Leuven), Dentistry, Leuven, Belgium. Proofread the manuscript.

^c Associate Professor; KU Leuven (University of Leuven), Department of Oral Health Sciences, BIOMAT & UZ Leuven (University Hospitals Leuven), Dentistry, Leuven, Belgium. Wrote the manuscript.

Correspondence: Professor Marleen Peumans, KU Leuven (University of Leuven), Department of Oral Health Sciences, BIOMAT & UZ Leuven (University Hospitals Leuven), Dentistry, Kapucijnenvoer 7, B-3000, Leuven, Belgium. Tel: +32-16-332744; e-mail: marleen.peumans@kuleuven.be

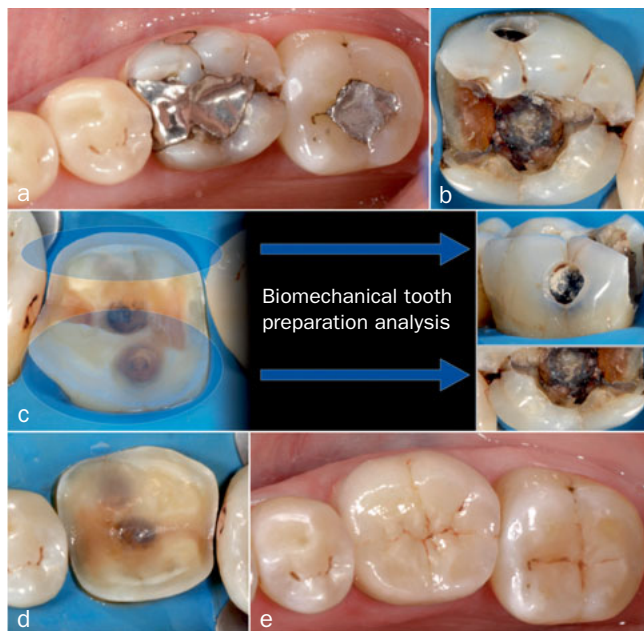


Fig 1 a. Initial situation. The patient complained of pain in the first mandibular molar during biting. This tooth showed an unacceptable amalgam restoration with caries underneath and a crack at the distal side. b. After removal of the amalgam filling, infectious dentin underneath became visible. The crack at the distal side ran towards the tooth center. The cusps were undermined by caries. c. The tooth was prepared for a lithium-disilicate glass-ceramic partial crown. All infectious dentin was removed. Due to the heavy loading on the buccal and lingual cusps and caries undermining the cusps, the cusps were reduced (minimum 1.5 mm) to a level at which enamel was supported by dentin. d. Final simplified preparation for a bonded nonretentive lithium-disilicate glass-ceramic partial crown. The preparation area is antifrangible. The dentin surface was protected by immediate dentin sealing (IDS) and the undercuts were blocked out with a highly filled flowable composite. The enamel prisms were sectioned obliquely to give good mechanical support to the restoration. e. The bonded lithium-disilicate glass-ceramic restoration shows a perfect integration with the surrounding tooth structure. An optimal bond of the ceramic restoration via the luting composite to the tooth is required to ensure a long-lasting restoration.

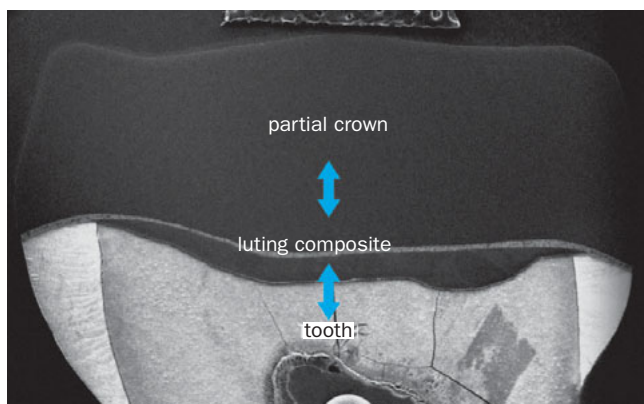


Fig 2 SEM photograph of a cross-sectioned molar restored with a bonded lithium-disilicate glass-ceramic partial crown. The section shows the different components of the bonded ceramic restoration-luting composite-tooth complex. The three components must function in synergy in order to restore the tooth in a durable way.

crowns, often also being referred to as “onlays” and “overlays”, have been documented to be more durable when posterior teeth with large defects need to be minimally invasively restored (Fig 1).^{5-8,20,25,31,40,52,67,93} Of the different factors that contribute to the success of a restoration, in particular the material properties and adhesive luting techniques have frequently been studied in the literature, resulting in fairly uniform guidelines for the dental practitioner.^{17,78} However, no consensus has been reached regarding a proper preparation form for this restoration type.^{2,10,21,22,41,53,78,88,89} Nevertheless, the tooth-preparation design is a very important factor determining the success of bonded indirect ceramic partial crowns.^{2,3} In this

article, a simplified nonretentive tooth-preparation concept is presented for these restorations. The aim of this simplified preparation concept is to create an adhesively luted ceramic restoration–composite cement–residual-tooth-structure biomechanical unit that functions in the most favorable way and results in a long-lasting restored tooth.

The basic principles of the bonded restoration-cement-tooth complex and their contribution to the durability of the restored tooth will be discussed first. Second, a correct biomechanical analysis before and during tooth preparation will determine the amount of tooth and cusp reduction. Third, the clinical protocol for restoring teeth with bonded ceramic partial crowns will be described step by step. Finally, the clinical durability of nonretentive bonded ceramic partial crowns will be discussed based on literature data.

1. Basic Principles of the Bonded Restoration-Cement-Tooth Complex

After restoring the tooth with a bonded partial ceramic crown, a strong biomechanical unit consisting of the restoration bonded to the remaining tooth structure is created (Fig 2). The three components of this complex should work in synergy to result in a long-lasting restoration.

1a. Tooth preparation

Today, bonded ceramic partial crowns are scientifically recognized as adequate tooth restorations for the posterior region. Despite the good medium- to long-term results, it is important to draw correct conclusions from failures that have occurred in clinical trials.^{6,31,40,52,67,80,93} The main reason for failure in all these clinical trials is (partial/total) fracture. A higher frequency of fractures is recorded for the older feldspar ceramics and leucite-reinforced glass-ceramics, compared to the newer and stronger lithium-(di-)silicate glass-ceramics, possibly reinforced with zirconia, that today

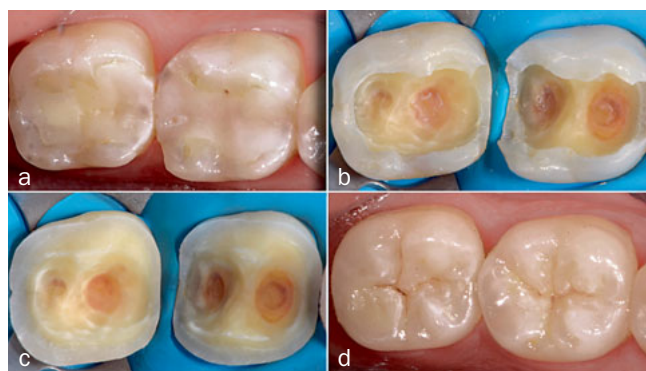

Fig 3 a. Initial situation. The old composite restorations with caries recurrence on both mandibular molars needed replacement. b. Removal of the existing restorations and caries resulted in deep, wide cavities. When kept, the lingual and buccal cusps would function as long cantilever arms. Reduction of all cusps was therefore indicated. c. The cusps were reduced (minimum 1.5 mm) to a level at which enamel was fully supported by dentin. The dentin surface was smoothed. All margins were located in enamel. The prepared tooth surface was then ready for IDS and out-blocking of the undercuts. d. Two lithium-disilicate glass-ceramic partial crowns were bonded with a light-curing restorative composite.

can be used for this indication.^{6,8,67,74} It should be noted that the geometry of the tooth preps in these clinical trials did not often match well with the material-specific properties of hard and brittle ceramic materials. Nonetheless, the fracture resistance of the bonded ceramic restorations should be increased. New guidelines for the preparation form of bonded all-ceramic restorations were formulated by Ahlers et al² and Arnetzl and Arnetzl.^{3,4} These guidelines describe eight points of interest. First, cavities designed for ceramics must have the simplest possible basic geometry. Second, an appropriate and uniform layer thickness of the restoration is recommended (minimum 1.5 to 2 mm). Third, corners and sharp edges must be avoided. Fourth, high tensile stresses should be avoided and must be transformed whenever possible into compressive stresses by changing the prep design. Fifth, stress peaks and sudden changes in cross-section should be avoided by soft and smooth transitions. Sixth, notch stresses must be minimized. Seventh, the contact surface with the ceramic restoration must be made as large as possible. Finally, enamel bordered restoration margins facilitate a stable and adhesive bond of the ceramic restoration via the luting composite to the remaining tooth structure and will thus permanently guarantee better marginal quality.

Fairly similar geometrically simplified preparation designs were tested *in vitro*^{4,10,60,62,83} and *in vivo*.^{5,7,40,64,75} In some laboratory studies, the teeth were prepared for the treatment of occlusal wear with so-called occlusal veneers.^{10,41,60,62,83} It must be emphasized that in all *in vitro* studies intact natural teeth were prepared, while in daily clinical practice moderate to heavily destroyed teeth are

most often prepared for ceramic partial crowns. Therefore, in this article the preparation design will be described starting from a real clinical situation, ie, a moderately compromised tooth (Fig 3). In addition, the nonretentive tooth-preparation design will be considered as part of an entire concept, resulting in the most favorable biomechanical loading of the bonded restoration-cement-tooth complex.

The main features of this modified tooth-preparation design are fourfold and described in Fig 4. After biomechanical analysis (see below), the preparation phase starts with removal of the existing defective restoration and selective removal of decayed and infected tissues (Figs 3a and 3b). Next, a smooth dentin surface is created with gradual and soft transitions between concavities and convexities (Fig 3c). No resistance and retention form is required. The preparation outline follows a smooth and fluid curve, with open angles to increase and ensure the mechanical stability of the restoration.

The tooth preparation consists of a dentin part that is (ideally) completely surrounded by enamel. As mentioned above, the prepared dentin surface should be clean and may not show sharp irregularities. This increases the internal adaptation and marginal fit of the partial crown when compared with a retentive tooth-preparation design, as was demonstrated *in vitro* by Kim et al.⁵⁰ The better the adaptation, the lower the thickness of the cement layer, the easier the restoration can be positioned onto the prepared tooth surface, the easier the cement will flow during seating and cementation, and the more precise the occlusion. If the cement layer can be reduced to the thinnest possible layer, there is less risk of interference with occlusion and articulation after cementation of the restoration. Poor marginal fit can exacerbate degradation of the cement in the oral environment, resulting in microleakage, marginal discoloration, recurrent caries, and periodontal disease.^{26,46} Although there is no consensus on the optimal internal cement space for adhesively luted ceramic restorations, an internal space of 50-100 μm has been advocated for good performance of composite cements^{65,86} (Fig 4b). A large internal cement space can cause higher polymerization shrinkage of luting cement and less optimal support to the ceramic restoration. In addition, bond strength of composite cements to glass ceramics was postulated to decrease with an increase of composite-cement film thickness.⁹

A flat surface also results in a lower C-factor, decreasing the polymerization stress of the luting composite compared to a cavity prep with a complex configuration.²⁴ However, one has to take into account that there is limited relaxation of polymerization stress due to flow because the luting composite is bonded at all sides. Feilzer et al²³ reported that when the thickness of the resin composite is thinned down, as when used as luting agent, the wall-to-wall polymerization shrinkage may be three times the normal linear contraction of bulk resin composite. This is one of the reasons why it is advisable to use a light-curing restorative composite for cementation, as the polymerization shrinkage is lower compared to a dual-curing luting composite with lower filler content.

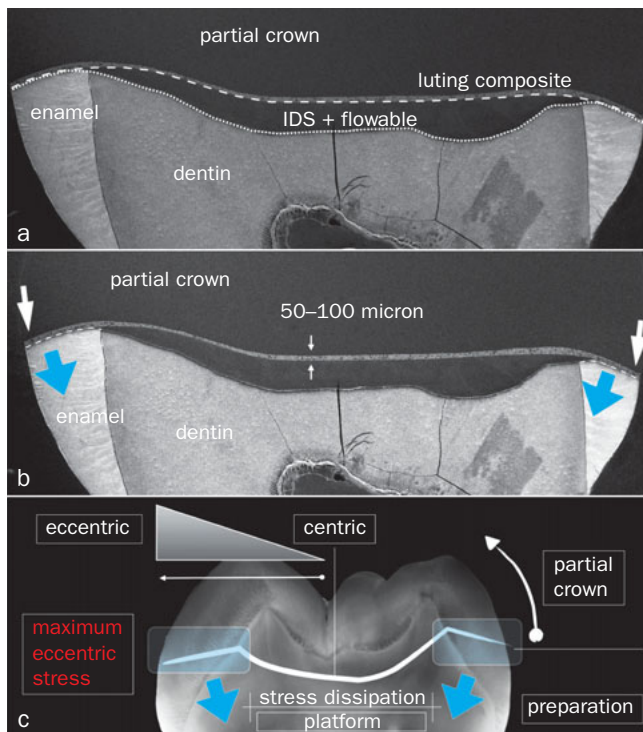


Fig 4 a. SEM photographs of the ceramic restoration-luting composite-tooth complex showing the four requirements of the tooth-preparation design. (1) The preparation area (white small-dotted line) must be antifrangible, as during occlusion and articulation, the working and non-working occlusal forces are mainly concentrated in the lower half of the tooth. (2) The prepared surface must be smooth without any abrupt transitions to decrease stress concentration at the restoration-luting composite-tooth complex. (3) After application of IDS and blocking out the undercuts with a flowable composite, a stress dissipation area is created (white long-dotted line). This means that the forces, absorbed by the restoration, are transferred in the most favorable way to the adhesive interface and the tooth, by converting the tensile stress in the ceramic and at the interface as much as possible into compressive stress. b. A fourth requirement is that the prep margins are precisely defined and the preparation allows for the best possible internal and marginal fit of the ceramic partial restoration. The luting area varies between 50-100 μm (small white arrows). Ideally, the prep margins are located in enamel (large white arrows), although this is determined by the extent of lesion. The enamel prisms must be cut obliquely to ensure maximum bond strength and to create optimal mechanical stability for the restoration (blue arrows). c. By sectioning the enamel prisms in an oblique way, the stresses will be mainly relocated in a centripetal way inside the tooth, not outside the tooth. The restoration will have the most stable support in the areas where the maximum eccentric stress is concentrated.

The prep margin is very precise and defined, allowing the dental technician to read the prep margin very clearly. Ideally, the prep margin must be located in enamel in order to obtain an optimal marginal seal and to give long-term stability to the large dentin adhesive surface.^{15,22} The preparation in enamel also follows the antifrangible concept and is able to support the restoration well. The enamel prisms must be sectioned obliquely (Figs 4b and 4c). As was shown by Giannini et al,³³ bonding to obliquely sectioned enamel results in a significantly higher bond strength than to horizontally cut enamel. This obliquely sectioned enamel will be completely supported by dentin. The stresses will be relocated in a centripetal way inside the tooth, not outside (Fig 4c). The restoration will benefit from the most stable support in the areas where the maximum eccentric stress is concentrated (Fig 4c). Final preparation of the enamel margin should be carried out after application of “immediate dentin sealing” (IDS).

Once the dentin surface has been adequately prepared, IDS is performed as part of the indirect two-visit workflow. This includes the formation of a high-quality hybrid layer upon preferential application of either a mild 10-MDP-based 2-step self-etch adhesive (ie, Clearfil SE Bond 2, Kuraray Noritake; Tokyo, Japan) or a 3-step etch-and-rinse adhesive (ie, Optibond FL, KerrHawe; Orange, CA, USA), each according to the instructions of the respective manufacturer. IDS immediately seals dentin and blocks water uptake through osmosis from dentin underneath. Placing a highly filled flowable composite on top of the adhesive layer enables to micro-selectively block out potential tooth-preparation under-

cuts (Figs 1d and 4a). IDS protects the freshly cut dentin surface, awaiting that the ceramic restoration is made by the dental technician. Post-operative sensitivity is thus prevented.^{63,76} Furthermore, IDS allows a stress-free dentin-bond development, which even in vitro has been documented to result in a significantly higher dentin-bond strength compared to delayed bonding (adhesive procedure just before cementation).^{18,39,58} Finally, the IDS layer (hybrid layer + adhesive layer + flowable composite) forms a stable and strong platform for stress dissipation during occlusal loading (Fig 4c). The micro-buildup with the well-stabilized hybrid layer creates a smooth and regular surface that allows for the most favorable stress distribution (mainly compressive stress) during occlusion and articulation.

A composite macrocore buildup is not indicated as this increases the stress on the recently formed hybrid layer. In addition, such a bonded core buildup has a lower elastic modulus and thus will flex more than the overlying ceramic restoration, by which high tensile stresses may develop in the ceramic at the interface with the cement, just below the loaded area. This can cause the formation of cracks in the ceramic at the interface, which may grow towards a total bulk fracture at a later stage.^{47,48} An exception can be made for an endodontically treated premolar when little amount of tooth structure is remaining. In this situation, a macrocore buildup can be made to provide more retention to the restoration and to achieve a better resistance form against lateral forces (Fig 5).

Regarding this new simplified tooth-preparation concept, it must be emphasized that this concept works only on the con-

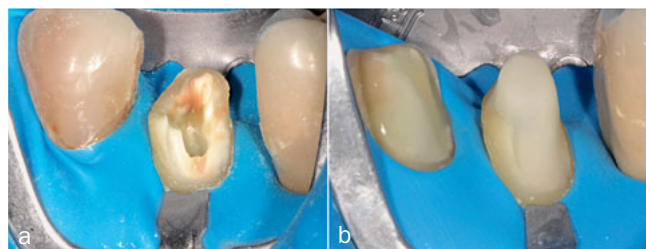


Fig 5 Macrocore buildup on an endodontically treated premolar. A fiber-reinforced composite (EverX Posterior, GC; Tokyo, Japan) is used to fill the pulp chamber and to constitute the macrocore buildup. It was covered with a highly filled flowable composite. This macrocore buildup was needed to provide retention to the restoration and to resist lateral forces during articulation.

dition that a high-quality bond is obtained with the existing tooth structure. If application errors are made in this regard, failures of the restoration can be expected in the short term.

1b. Ceramic restoration

Regarding the ceramic materials for bonded indirect restorations, the most favorable results *in vivo* and *in vitro* are obtained with the strongest etchable ceramics nowadays available on the dental market, ie lithium-disilicate glass ceramics.^{7,8,10,40,56,60,62,64,75,83,95} Today, so-called zirconium-reinforced lithium-silicate glass ceramics are also available. Lithium-(di)silicate glass ceramics present with a similar wear behavior as enamel.⁸¹ At the moment, the commercial glass ceramic e.max CAD/e.max Press (Ivoclar Vivadent; Schaan, Liechtenstein) is the most studied lithium-disilicate glass ceramic in the literature.

The thickness of the ceramic restoration (minimum 1.5 mm) must be as uniform as possible, in order to have a more homogeneous distribution of stresses and forces inside the restoration, the prepared tooth surface and across the adhesive interface during occlusal loading. This is realized if the guidelines for this preparation design as described above are followed. Promising results were recorded *in vitro* with “occlusal veneers” for the treatment of occlusal wear in thicknesses of 0.5 -1 mm, especially when the restorations were bonded to enamel.^{10,41,62,84} At the moment, no *in-vivo* studies are available that show that these minimally invasive occlusal veneers work well in the medium- to long-term. The main indication for a partial ceramic crown presented in this article is to restore moderately to severely compromised teeth. As it is the aim to make a durable restoration with a proven clinical performance, the restoration must have a minimum thickness of 1.5 mm.^{3,56} In addition, the partial crown must restore the natural anatomy of the tooth (Fig 6). This means correct inclination of the buccal and lingual cusps (outer and inner inclination), just in order to have a loading that will be transferred to the tooth correctly. During occlusal loading the stresses must be relocated in a centripetal way from the periphery to the center of the tooth, in order to allow the tooth to work like a natu-

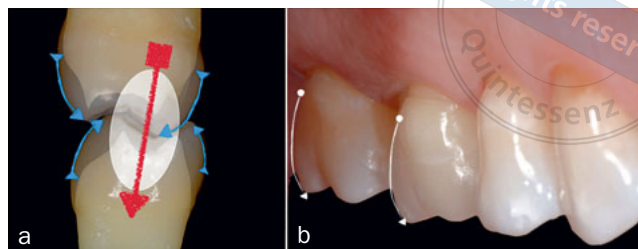


Fig 6 a. The partial crown must restore the natural anatomy of the tooth (blue arrows). The buccal and lingual cusps must have the correct inclination in order to induce loading that is transferred correctly to the tooth (red arrow). This means that during occlusal loading, the stresses are relocated centripetally from the periphery to the center of the tooth. b. The buccal surface of the overlay on the maxillary first molar has a correct inclination (white arrow) for optimal stress distribution in the restored tooth.

ral, intact tooth and to be able to dissipate the loads much better along the long axis of the roots.

In this proposed concept, the retention of the restoration mainly relies on bonding. Hence, the quality of the bond to the restoration is of key importance and is a dominant factor required for the long-term success of the bonded lithium-(di) silicate glass-ceramic restoration. Composite cements provide the strongest and most durable bonding of ceramics to tooth structure and contribute to a higher ceramic strength.⁹¹

It is generally accepted that adhesion of composite cements to ceramics is provided by two major mechanisms: micromechanical interlocking and chemical bonding. Micromechanical interlocking or micro-retention can be provided upon hydrofluoric-acid (HF) etching, whilst a silane coupling agent increases the wettability of the ceramic surface and provides a primary chemical bond.⁹¹ Various glass ceramics differ in chemical composition and microstructure, by which it is necessary to establish bonding procedures according to the glass-ceramic type.^{19,55,73} Lithium-disilicate glass ceramic requires a shorter HF acid-etching time (20 s) compared to feldspatic and leucite-reinforced glass ceramics. Regarding etching time, it is important to follow the instructions of the manufacturer.

1c. Luting composite

The strongest luting composite must be selected to create a good support for the partial ceramic crown; the antifrangible margin preparation (Fig 4b) is a key determinant as well. Therefore, a light-curing restorative composite is preferred to be used as luting agent. A restorative composite is more wear-resistant and has better physico-mechanical properties than a conventional dual-curing luting composite with lower filler content. In two *in vitro* studies, feldspatic ceramic blocks (Vita Mark II, Vita; Bad Säckingen, Germany) with a 4-mm thickness and lithium-disilicate glass-ceramic blocks (e.max CAD HT, Ivoclar Vivadent) with even an 8-mm thickness were bonded to flat dentin surfaces using different luting composites.^{45,82} Both studies showed that the micro-tensile bond strength of the light-curing restorative composite applied in combination with a 2-step self-etch

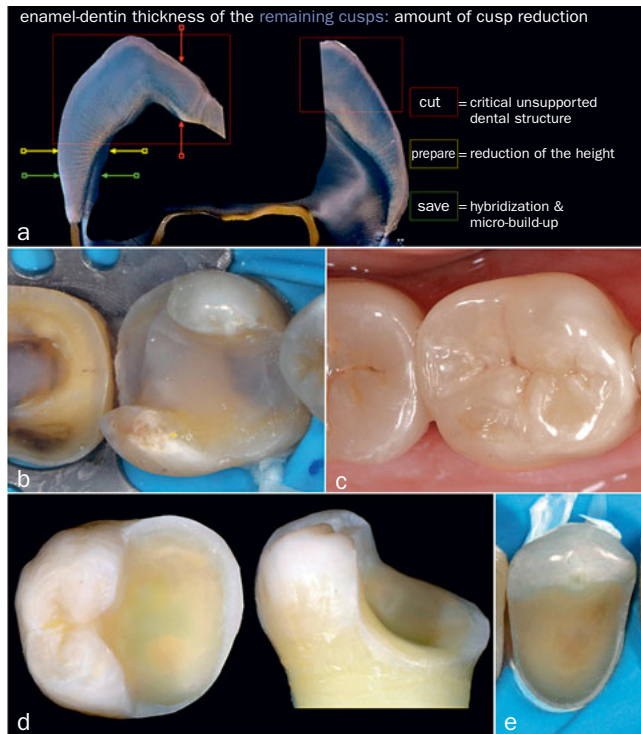


Fig 7 a. The enamel-dentin thickness of the remaining cusps and the cavity depth determine the amount of flexure of the cavity walls. For a bonded indirect lithium-disilicate glass-ceramic restoration: (1) the non-undermined cusp (right side) is reduced with 1.2-1.5 mm if the cavity is deep and wide. The long cantilever arm would otherwise flex too much during occlusal loading and can result in fracture after long-term clinical functioning. (2) The greatly undermined cusp (left side) should be reduced to the level at which enamel is supported by dentin. However, if there is a little wall left where enamel is not completely supported by dentin (yellow arrow), this little wall can be kept, as the flexure arm is dramatically reduced by reducing the cusp to this level. It is preferable to block out the undercuts with a flowable composite (green arrow) and to keep the margin in enamel in the cervical area in order to obtain an optimal bond at that cervical margin. b. Shortcoming in the preparation on the first molar. The intention was to be less invasive by keeping the two cusps. These cusps were, however, not stable enough to resist flexure during occlusion and articulation, having resulted in rapid mechanical degradation of the adhesive interface. c. After cementation of the lithium-disilicate glass-ceramic partial crown with a light-curing restorative composite, the larger luting area at the buccal side can be noticed. This will be a weak area in this restoration. d. The thick cusps on the prepared molar can be kept. The remaining cusps are able to resist the forces during occlusion and articulation and will not flex easily. Consequently, the interface will be less stressed. e. The thick buccal cusp of the maxillary premolar was maintained for esthetic reasons.

adhesive (Clearfil SE Bond, Kuraray Noritake) was significantly higher compared to the tested conventional dual-curing luting composites applied with their accompanying adhesives. Similarly, other in vitro studies showed that a light-curing restorative composite can be used to lute thick ceramic/composite restorations.^{35,38} To obtain this result, it is important that the restorations transmit light sufficiently, sufficiently powerful LED light-curing units are used, light curing is conducted from different sites and that the curing time is prolonged extensively and sufficiently. The curing time should be 60 seconds per surface (vestibular, lingual/palatal, occlusal for premolars, occlusal at mesial and distal side for molars). In all the above-mentioned in vitro studies, fairly translucent ceramics/composites were used (with an opacity of about 50%). In general, for the fabrication of ceramic partial crowns, translucent lithium-disilicate glass ceramics are used as they give the most natural outcome. Several clinical trials have also shown that inlays/onlays bonded with a light-curing restorative composite function well in the long term.^{12,31,40,52,80}

Cement excess removal is easier thanks to the higher viscosity of the restorative composite as compared to the significantly more fluent and thinner luting composites. Specific restorative composites such as Clearfil AP-X (Kuraray Noritake) were for instance found to have near-ideal viscosities for luting, even when used at room temperature. Preheating stiffer restorative composite might be indicated to decrease viscosity; preheating composite in turn facilitates the seating of the restorations and contributes to a higher degree of conversion.^{1,71} Clinically, luting with a

light-curing restorative composite gives the practitioner much more control on complete removal of cement excess and substantially increases the work time to accurately remove cement excess, especially in the difficult interdental areas. Good radio-opacity of the luting composite (higher than that of dentin) is required in order to visualize potential residual excess of composite after cementation. Having a nearly unlimited work time (when the dental unit light is moved away and/or an orange light filter is used on a dental operating microscope or the light source connected to magnifying glasses), multiple ceramic restorations in light of a quadrant restorative treatment is clinically feasible.

2. Biomechanical Analysis

Dental tissues respond biologically to stresses and strains imposed during mastication. Teeth compromised due to extensive carious lesions or large restorations tend to weaken the tooth. The stresses in teeth associated with these conditions may lead to cusp fracture. It is essential to prevent fractures by starting from a clear concept with a sound tooth-preparation design and by anticipating the stresses of mastication that may be imposed to the remaining tooth structure. For these reasons, the restorative procedure of a bonded (direct/indirect) restoration in the posterior region always has to start with a profound biomechanical analysis of the tooth. This includes analysis of the forces and loading on the tooth during occlusion and articulation, as well as analysis of the amount and quality of the remaining tooth structure.

The chewing forces and occlusal loading imposed on a tooth are determined by the anatomic position of the tooth

in the arch, the patient's occlusion and musculature, and the functional and parafunctional load on the tooth. The occlusal loads increase from anterior towards posterior, from mesial towards distal, and from premolars towards molars. Increasing loads will automatically increase the risk of fracture. The occlusion and articulation on the tooth to be restored should beforehand be registered with articulation paper, in order to analyse the strength and location of the occlusal contacts at the future restoration margins and on the remaining cusps.

The amount and quality of the remaining tooth structure is analysed by evaluating the size of the existing restoration and the presence of decay, defects, cracks and wear facets.

The type, size and depth of the cavity preparation determines the reduction in fracture resistance of the tooth to a great extent. The fracture resistance of intact teeth, teeth with a cavity prep and restored teeth was studied in several in vitro studies using different methods such as finite element analysis, measuring cuspal deflection or cusp stiffness during occlusal loading, and by fracture tests.^{34,36,42,59,66,70,77} These studies show that increasing the depth of the cavity, increasing the isthmus width and loss of the marginal ridges resulted in the largest reduction in fracture strength. The fracture resistance of teeth with cavities gradually decreases for teeth having solely an occlusal class-I cavity, to teeth undermined by a two-surface class-II cavity, and finally teeth exhibiting a three-surface MOD cavity preparation having the lowest fracture resistance. Large MOD cavities resulted in a decrease in fracture resistance by 59% to 76%, compared to that of intact teeth.^{13,16,77,87} Other in vitro studies recorded that occlusal loading (150 N) of premolars with an MOD cavity resulted in a widening of the cusps over a distance of 114-179 μm .^{36,59} After direct restoration of a tooth with composite, a cusp deflection of about 7-9 μm was still measured. One also has to take into account the changes that take place at the cusps due to polymerization shrinkage of the composite, as was shown by Tantbirojn et al⁹⁰ and González-López et al.³⁷ The adhesive is also a determining factor. The observed effects will be magnified if the bond is inadequate. According to Reeh et al,⁷⁷ endodontic procedures alone (access preparation, instrumentation and obturation) have only a small effect on the tooth, reducing its relative stiffness by 5%. This reduction in stiffness did not depend on the sequence of the endodontic treatment before or after cavity preparation. Other in vitro studies recorded a more pronounced decrease in fracture resistance after endodontic treatment.^{42,70} The least favorable situation regarding fracture resistance of the prepared tooth is an endodontically treated premolar/molar with a large MOD cavity.^{32,36,42,70,77} In these teeth, complete cusp coverage (overlay) is needed to increase the fracture resistance of the restored tooth.

In summary, the reduction in fracture resistance will be most pronounced in teeth with large, wide and deep cavities. Bonding of a restoration to these cavity walls reinforces the tooth, but flexure will still occur during occlusal loading. This results in mechanical degradation of the adhesive interface. Along with hydrolytic and enzymatic bond

degradation, loss of adhesion will occur with time, leading to open coronal margins, marginal discoloration, secondary caries, increased flexure of the cavity walls, and possible fracture of the cusp. In these kind of large, wide and deep cavities, where the cusp functions as a long cantilever arm, cusp reduction followed by cusp coverage increases the fracture resistance of the tooth and the clinical longevity of the restoration^{4,42,57} (Fig 7a). For a bonded indirect ceramic partial crown, one should avoid keeping cusps that flex during occlusal loading, as they will negatively influence the longevity of the restoration (Figs 7b and 7c). Hence, a cusp can be maintained in the following situations:

1. A very thick cusp that is able to support occlusion and articulation (Fig 7d). The cusp contributes to a great extent to the fracture resistance of the tooth. Keeping this part of the tooth structure does not provide many problems of instability to the residual dental structure. The remaining cusp is able to resist the forces during occlusion and articulation and will not flex easily. Consequently, the interface will be less stressed. A shortcoming in these situations is that the occlusal margin is not protected. Enhanced exposure of the restoration margin to occlusal wear results in more extensive marginal discrepancies.⁸⁸ In addition, as enamel wears more than ceramic in these areas, positive ceramic steps will be formed after long-term clinical functioning. If these steps are not adjusted, initial cracks may be initiated at exactly these points.^{31,51} Therefore, when making a partial crown that does not cap all cusps, the fit and adaptation at the occlusal surface must be perfect and the luting marginal gap must be kept as small as possible.
2. A thick buccal cusp of a maxillary premolar can be maintained for esthetic reasons, but the strength of the finally restored tooth will not be the same as that of one restored with a circumferential preparation (Fig 7e). In these situations, we need to evaluate the latero-trusive path and the guidance of the premolars. In case of a missing first molar, the premolars are often overloaded during occlusion and articulation.

In all other situations, the cusps are better reduced as this allows the ceramic restoration to function in the best possible condition, namely under compression. Reducing the cusps contributes to the antifragile preparation form. In general, for bonded indirect lithium-disilicate glass-ceramic restorations, the cusps, where enamel is supported by dentin, are reduced with 1.2 to 1.5 mm. This is a slightly more invasive approach than what is often described in the literature, where cusps 2.0 to 2.5 mm thick are kept.^{5,53} The main goal of this minimally hazardous dentistry is to create a long-lasting restoration-cement-tooth complex.

3. Clinical Protocol, from Concept to Clinic

The different steps of the clinical protocol are explained in detail and documented with clinical pictures (Figs 8-20).

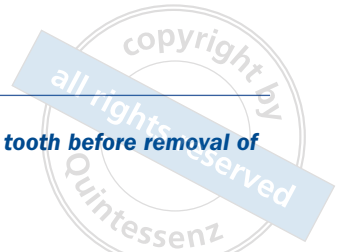


Fig 8 a. Initial situation. Maxillary molar with unacceptable amalgam restoration. Large marginal defects are noticed. b. Biomechanical analysis of the buccal part of the tooth. The presence of cracks decreases the fracture resistance of the tooth. The wear facets indicate heavy loading during occlusion and articulation. One can expect the buccal cusps to be undermined. Cracks are noticed at enamel surrounding the amalgam restoration. c. Biomechanical analysis of the palatal side of the tooth. Similar as at the buccal side, open margins and wear facets can be observed. A crack line is noticed at the distal marginal ridge.

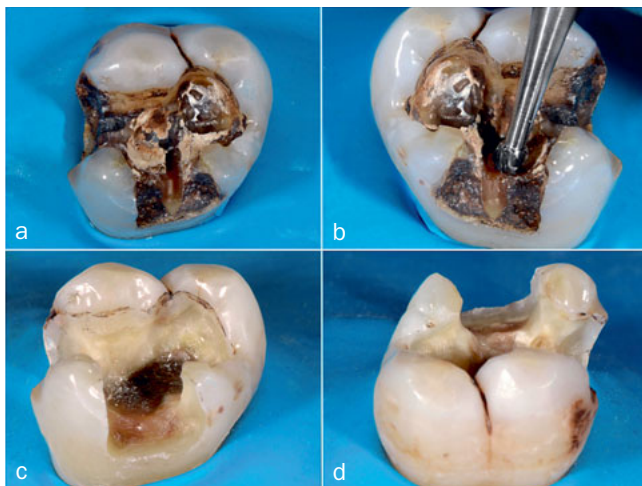


Fig 9 a. The unacceptable amalgam restoration was removed in a minimally invasive way with a multiblade tungsten carbide bur. An ultrasonic device with water cooling can be used to remove the last pieces of amalgam at a low biological cost. b. Caries-infected dentin was removed with a round tungsten carbide bur (Komet H1SEM, Brasseler; Lemgo, Germany) dry and at low speed (7000 rpm). A centripetal approach was followed. This included starting at the periphery towards the critical points. In this way, possible pulp exposure would have been programmed. It is very important that all caries-infected dentin be removed in order to realize a good-quality hybrid layer that will remain stable in the long term. c. After removal of the restoration and all infected tissues, a more detailed biomechanical analysis takes place. The thickness and quality of the cusps, the thickness of marginal ridge and the presence of crack lines was controlled. At the buccal side, the cusps were undermined. Cusp reduction was needed. d. At the palatal cusps, enamel was supported by dentin. Because of the heavy occlusal loading (wear facets) and the crack line at the distal side, the palatal cusps were also reduced.

3a. Biomechanical analysis of the tooth before removal of the defective restoration (Fig 8)

See Fig 8.

3a. 1. Evaluation of the quality and amount of remaining tooth structure

Size and depth of the existing restoration, decay and defects will inform the dentist about the most optimal restoration type (direct versus indirect; cusp capping or no cusp capping).

A radiograph shows the depth of the existing restoration and caries, and the risk of pulp exposure.

Evaluate the future location of the proximal prep margin. Take correct measures in case of deep subgingival margins. Gingival correction without or with removal of the supporting bone can relocate the margins iuxta- or supragingival.⁹⁴ Removal of the supporting bone is indicated when the biologic width has been invaded. A non-invasive alternative of surgical crown lengthening to bring the margins supragingivally is deep margin elevation (DME). This technique proposes the application of composite resin in the deepest part of the proximal areas in order to reposition the cervical margin supragingivally, which is expected to facilitate isolation and improve impression-taking and adhesive luting of the indirect restoration.^{17,49,61} Several in-vitro studies show promising results with DME.^{29,43,79,96} However, the influence of the DME technique on clinical performance, longevity of the restorations and periodontal health is not yet known.⁴⁴ A 12-month clinical trial showed that DME is a clinically sensitive technique, especially when performed on deep subgingival margins.²⁸ A higher incidence of bleeding on probing was recorded on teeth treated with DME and in coincidence with deep margins placed at or closer than 2 mm to the bone crest.

Next, the tooth to be restored is analysed for presence of cracks and fractures. These critical areas decrease the tooth's fracture resistance. The presence of wear facets indicates heavy loading during occlusion and articulation. Cusp capping in these regions will be needed in case of a bonded indirect lithium-disilicate partial crown.

3a. 2. Analysis of forces and loading on the tooth to be restored

Attention should be paid to the patient's musculature, functional/parafunctional activities, intensity and direction of the forces, location and strength of the contact points, and loading of the cusps.

3b. Rubber-dam isolation

Strict rubber-dam isolation is required in order to perform a high quality adhesive procedure (IDS and blocking out the undercuts). It is preferable to isolate 4-5 teeth under rubber-dam before starting the preparation as isolation at this moment is easier than after prepping. In addition, the dentist will have a better visibility during prepping when the teeth are isolated under rubber-dam.

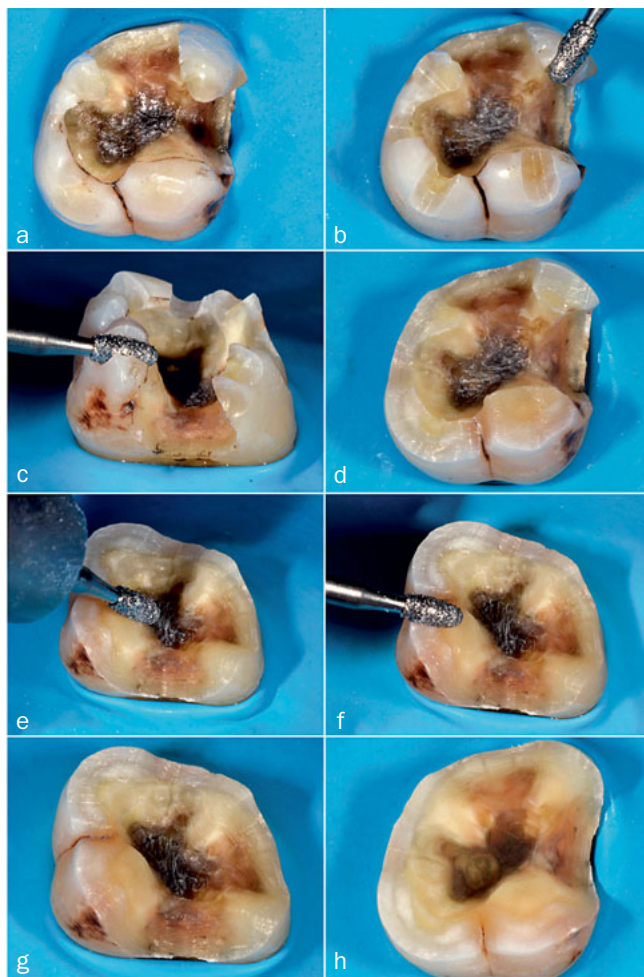


Fig 10 After thorough biomechanical analysis, it was decided to reduce all cusps. This contributes to a more equal and favorable loading on the tooth and interface, and increases the longevity of the restoration. a. Before reduction. b. Depth grooves (± 1.4 mm) were made on each cusp and the marginal ridge. An olive shaped diamond bur (833G314014; Hager and Meisinger; Neuss, Germany) was used as a calliper. c. The same bur was used to cut the cusps circumferentially, guided by the depth grooves prepared with the olive-shaped diamond bur. d. After cusp reduction, the dentin support was analysed cusp by cusp. e. The tooth preparation was finalized using the same olive bur. Smooth transitions were created inside the preparation to remove sharp irregularities. f. Also the prep outline was made smooth with the same bur. g and h. Final tooth prep before (g) and after (h) sandblasting with Al_2O_3 (30 μm).

3c. Tooth preparation

After removal of the restoration and all infected tissues, the remaining tooth structure is evaluated (Fig 9). A more detailed biomechanical analysis is then performed to control the thickness and quality of the cusps (enamel supported by dentin), the thickness of the marginal ridges and to detect the possible presence of crack lines. Thin, unsupported cusps behave like a cantilever wall and must be reduced with at least 1.5 mm. By reducing the cusps (Fig 10), the flexural behavior of the cantilever wall is dramatically re-

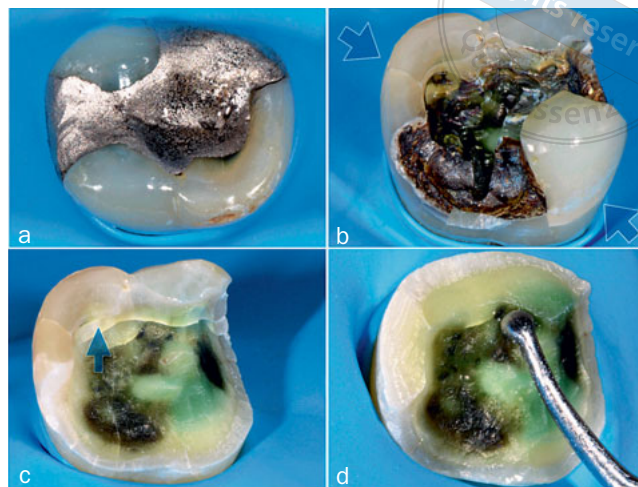


Fig 11 a. Initial situation: amalgam restoration that needed replacement because of the presence of several severe cracks in the surrounding tooth structure. b. After removal of the existing restoration, the cracks are clearly visible at the base of the lingual and buccal cusps (blue arrows). c. The mechanical resistance of the cusp walls was tested with an excavator. At the buccal side, the cusp fractured spontaneously at the level of the crack line. At the lingual side, the crack lines are clearly visible. The lingual cusp resisted the pressure executed with the excavator. d. Reduction of the lingual cusps more or less at the level of the crack. The preparation margin was kept in enamel.

duced and the geometry of the forces is changed. Compressive instead of tensile forces will work mainly on the residual dental structure. Guidelines to treat teeth with crack lines are demonstrated by clinical cases (Figs 11 and 12).

3d. Immediate dentin sealing (IDS) using a gold-standard adhesive and microselective out-blocking of undercuts

Documented gold-standard adhesives are the 3-step etch-and-rinse adhesive Optibond FL (KerrHawe) and the mild 2-step self-etch adhesive Clearfil SE Bond (Kuraray Noritake).^{14,72} The adhesive is applied according to the instructions of the respective manufacturer (Fig 13). After polymerization of the adhesive, a highly filled flowable composite is applied to micro-selectively block out undercuts in the dentin preparation (Fig 14). At the same time, deep, tight and complex cavities are corrected geometrically. The application of the flowable composite will stabilize and protect the newly formed hybrid layer and increase its degree of conversion.

3e. Re-preparation of the enamel margins (Fig 15)

See Fig 15.

3f. Cementation of the lithium-disilicate ceramic partial crown (Figs 16–19)

- Check the fit and marginal adaptation of the ceramic partial crown (Fig 16).
- Adhesive treatment of the lithium-disilicate glass-ceramic partial crown (Fig 17).

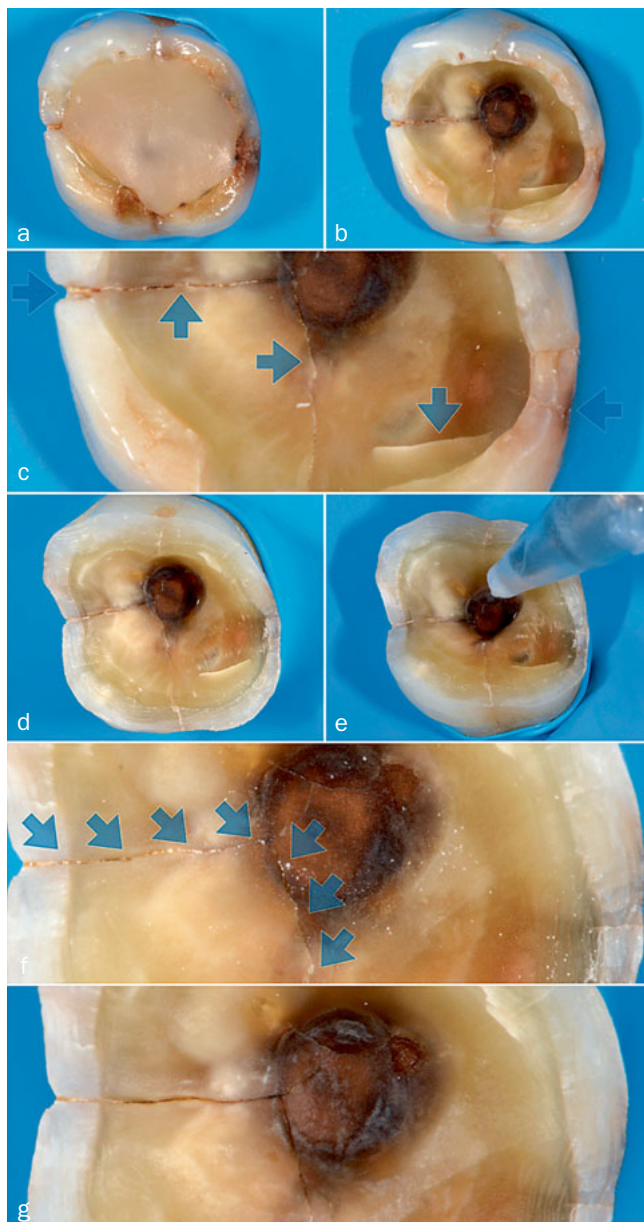
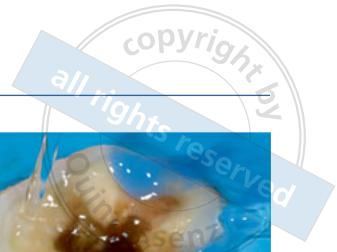

Fig 12 a. Initial situation. Old, large, unacceptable class-I composite restoration. Cracks are present at the mesial, distal and palatal side. b. Residual dental structure after removal of the existing restoration and infected dentin. Crack lines are running from the mesial and palatal side towards the center of the cavity. In this deep, wide cavity with completely undermined cusps, total cusp reduction is needed. c. Detailed analysis of the cracks in the tooth (blue arrows). d. The cusps were circumferentially reduced until a level that enamel was completely supported by dentin. e. The crack was sandblasted with Al₂O₃ powder (30 μm). f. After sandblasting, the crack line is contaminated with the non-hydrosoluble Al₂O₃ powder particles. g. Cleaning of the crack line with sodium bicarbonate (40 μm) air polishing, followed by generously rinsing with an air-water spray. The prepared tooth was ready for immediate dentin sealing.

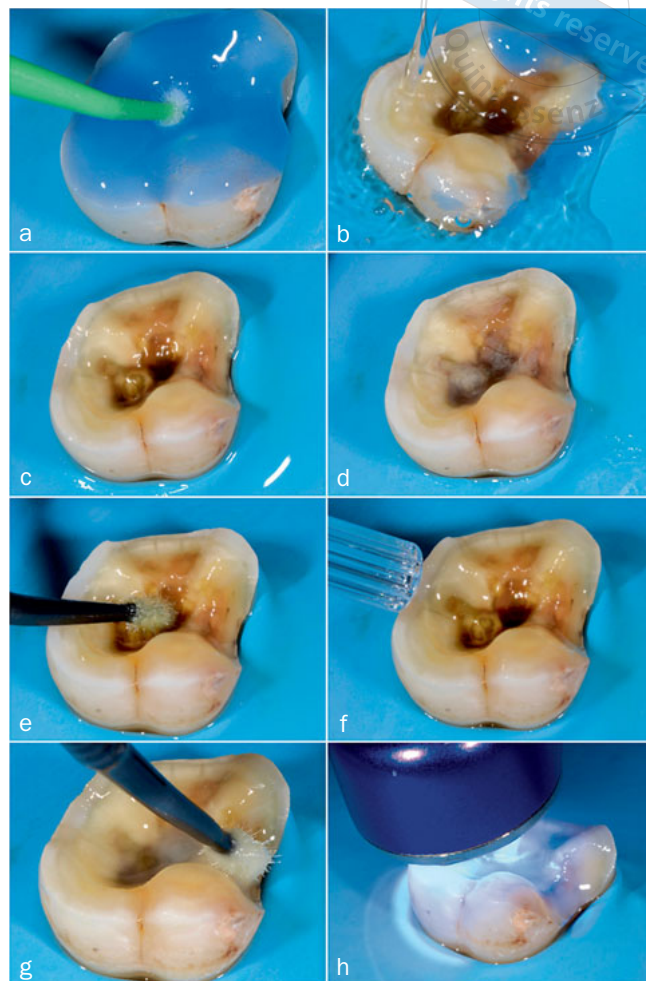


Fig 13 a. A 3-step etch-and-rinse adhesive (Optibond FL, KerrHawe) was applied according to the instructions of the manufacturer. First, the dentin surface was etched with phosphoric acid (35%) gel for 15 s. b. The etch gel was rinsed for 15 s. c. A wet dentin surface is visible. d. The dentin surface was gently air dried for 5 s. e. Immediately after drying, the dentin was rehydrated by generous application of the water-ethanol based primer, while gently rubbing the primer into the dentin surface with a microbrush for at least for 20 s. f. Gentle evaporation of the solvent contained in the primer by air drying for 5 s. g. The particle-filled bonding agent was applied. A uniform adhesive layer was created by moving the bonding gently over the whole surface. h. The adhesive was light-cured for 20 s with a high-intensity light-curing unit (1200 mW/cm²). The tip of the light-curing unit must be placed as close as possible to the surface.

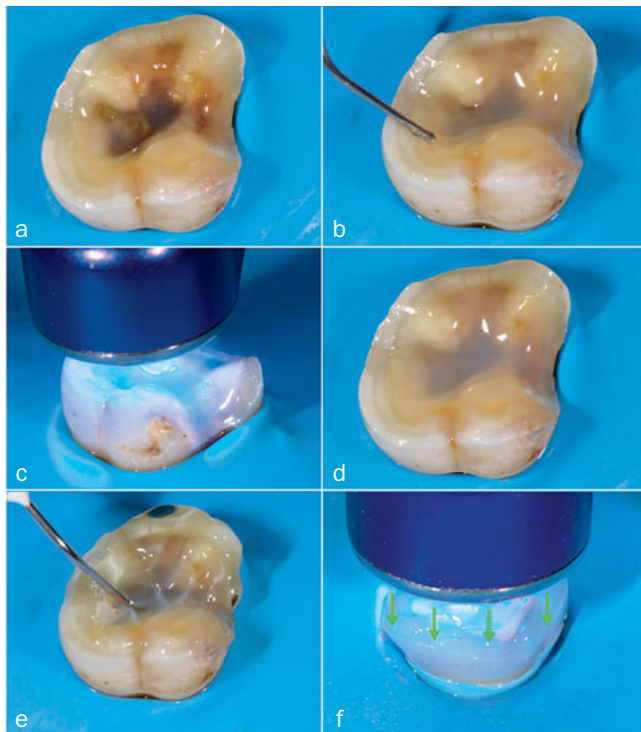


Fig 14 a. Hybridized dentin surface, having used a 3-step etch-and-rinse adhesive. b. Microselective out-blocking of all undercuts with a highly filled flowable composite. The flowable composite was applied centripetally, ie, from periphery to the center of the dentin surface. c. The flowable composite was light cured for 40 s with a high-intensity light-curing unit (1200 mW/cm²). The tip of the light-curing unit must be placed as close as possible and perpendicular to the surface. d. After IDS and blocking out the undercuts with a highly filled flowable composite, a perfect adhesive surface was created: smooth and without undercuts. e. Application of glycerine gel on the layer of flowable composite to remove the oxygen-inhibited layer at the surface. f. Complete polymerization throughout the glycerine gel for at least 20 s.

- Adhesive treatment of the tooth prep to lute the ceramic partial crown (Fig 18).
- Cementation of the ceramic partial crown (Fig 19).

3g. Finishing and polishing of the restoration margins (Fig 20)
See Fig 20.

4. Durability of Bonded Ceramic Partial Crowns

The durability of bonded ceramic partial crowns is determined by several factors, ie patient, operator, materials, amount and quality of the tooth structure to be bonded to and the restoration maintenance.

Regarding the patient factor, high caries risk, heavy occlusion/bruxism and poor oral hygiene have a considerable influence on the clinical performance of restorations. Caries recurrence is rarely seen in clinical trials, as these restorations are commonly placed in motivated patients with low

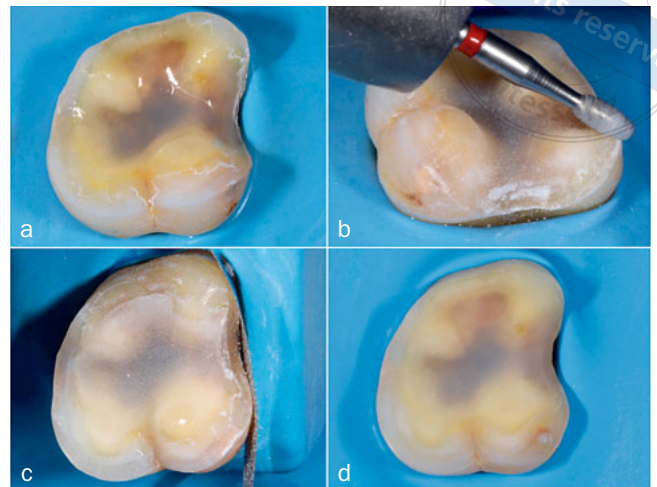


Fig 15 a. The gel was rinsed off with an air-water spray, upon which the prepared tooth surface was air dried. b. The enamel margins were re-prepared with a fine-grit olive-shaped diamond bur (833F314012, Hager and Meisinger) at medium speed without water. The bur was inclined 45 degrees to section the prisms obliquely. c. The interproximal areas were finished with a medium-grit metal strip. d. The final antifrangible tooth preparation, just before impression taking. A large dissipation platform was created. The preparation margins in enamel were well defined.

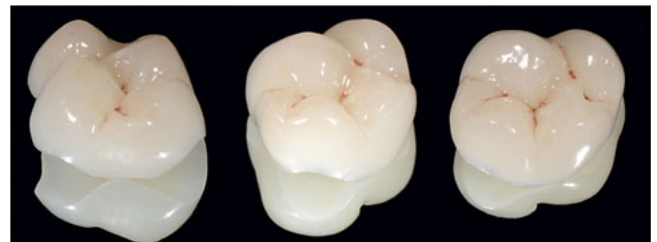


Fig 16 Monolithic lithium-disilicate glass-ceramic partial crowns made in e.Max Press (HT, Ivoclar Vivadent).

caries risk. Because of the higher cost of the restoration, most of the patients have a high socio-economic status and maintain good oral hygiene.

Bruxism also has a negative effect on the durability of bonded indirect ceramic partial crowns, as restoration fracture is more frequently recorded in patients with bruxism.^{5,6,67,93} In these clinical trials, feldspathic or leucite-reinforced glass ceramics were used. In the retrospective analysis of Belli et al,⁸ the fracture rate of lithium-disilicate glass-ceramic onlays (e.Max CAD, Ivoclar Vivadent) was significantly lower compared to that of leucite-reinforced glass-ceramic onlays (Empress CAD, Ivoclar Vivadent). Lifetime estimations showed that only 10% of the e.Max CAD (Ivoclar Vivadent) onlays will fail due to catastrophic fracture after 30 years, while Empress CAD (Ivoclar Vivadent) onlays were estimated to reach a 10% fracture rate already at 10 years of service.

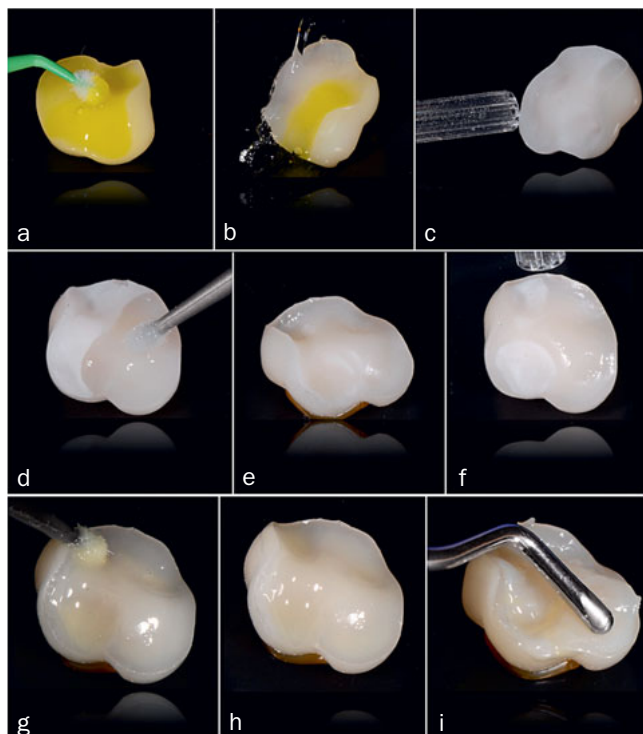


Fig 17 a. The inner side of the lithium-disilicate glass-ceramic partial crown was etched with HF acid-etch gel (9.6% buffered porcelain etch, Ultradent; South Jordan, UT, USA) for 20 s. The gel was applied over the whole inner surface. The action of the acid was increased by rubbing with a microbrush. b. The HF acid-etch gel was rinsed off very carefully with an air-water spray for 60 s. c. Next, the surface was dried with air. d. A drop of fresh silane (Monobond Plus, Ivoclar Vivadent) was applied onto the etched ceramic surface. e. It must wet the whole inner surface. f. After 60 s, the silanated surface was actively air dried to remove residual solvent. g and h. The particle-filled bonding agent was applied on the whole silanized surface. Premature polymerization by the operator light must be prevented. i. A light-curing restorative composite was applied at the inner surface. It was spread out with a smooth instrument over the whole surface, until the composite covered the margins.

Next, the operator also co-determines the durability of the restoration to a large extent. He has to ensure that the clinical procedure is carried out accurately and correctly. Placement of bonded indirect restorations requires the clinical execution of a highly technique-sensitive protocol. Profound knowledge of adhesive techniques by the operator is required. This was shown in a 4-year clinical trial of Frankenberger et al,³⁰ who evaluated ceramic inlays/onlays placed by two operators with different levels of experience in placing adhesive restorations. Significantly more failures were recorded for the unexperienced operator (24.6%), compared to the experienced operator (2.6%). Therefore, in order to reduce the number of application errors during the clinical procedure, the protocol must be simplified, standardized and easily reproducible as proposed in this article.

Regarding the amount and quality of the remaining tooth

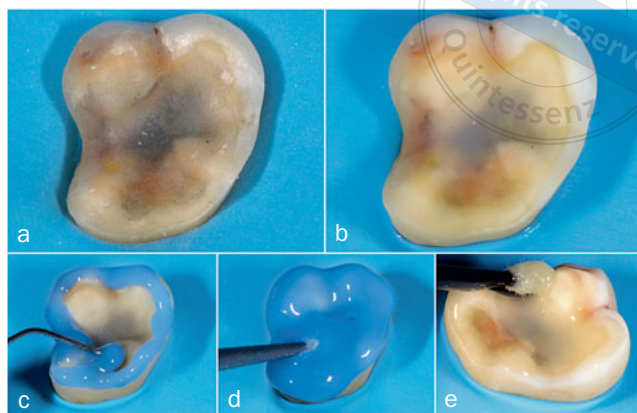


Fig 18 a. Strict isolation under rubber-dam is required. After removal of the temporary restoration, the prepared surface is contaminated. b. The surface was slightly roughened by air abrasion (30 µm) for 5 to 10 s. c. Phosphoric-acid (35%) etch gel was applied on the whole prepared tooth surface. The gel creates a microretentive etch pattern on the prepared enamel and cleans the dentin surface covered with the IDS layer. d. The phosphoric acid-etch gel was scrubbed onto the tooth surface with a microbrush for 30 s. e. After rinsing and drying, a drop of the particle-filled bonding agent was applied on the whole prepared tooth surface with smooth movements. Premature polymerization by the operator light must be prevented.

structure, a deep cervical cavity outline ending in dentin is reported as a risk factor for the survival of bonded indirect ceramic restorations.^{11,93} One has to keep in mind that these teeth are often heavily compromised with a low amount of sound tooth structure available to bond the restoration to. In addition, strict isolation is more difficult to obtain when restoring teeth with deep cervical margins.

Tooth vitality is another factor determining the restoration survival in several clinical trials. Vital teeth perform significantly better than non-vital teeth.^{6,67,93} Here too, one has to be aware that non-vital teeth are in general more heavily destroyed with less tooth structure available to bond the restoration to.

As described in our protocol, the most optimal bond to dentin is obtained using either a 3-step etch-and-rinse or a 2-step self-etch gold-standard adhesive. This is confirmed

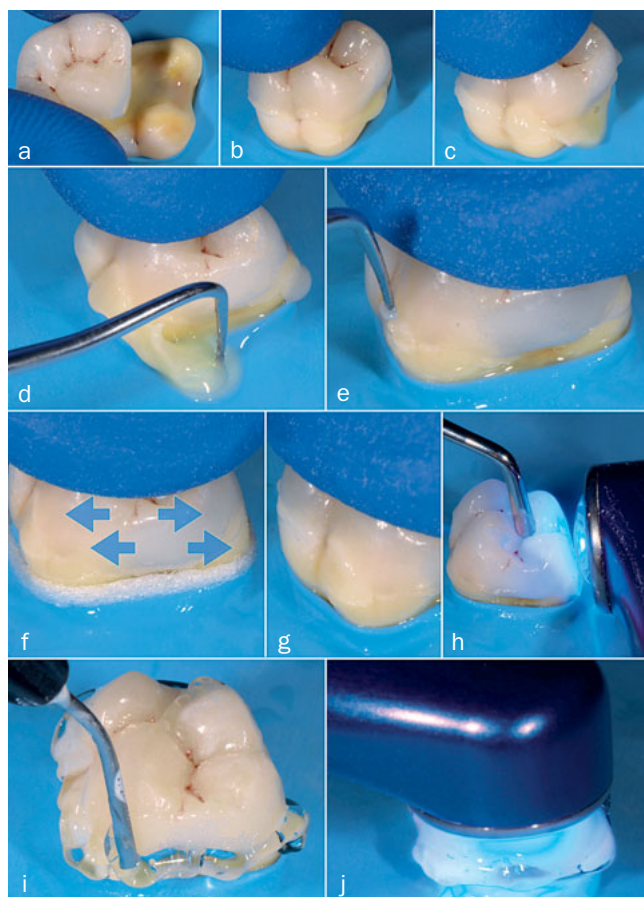


Fig 19 a. The partial crown filled with luting composite was gently positioned on the prepared tooth surface. b. The right path of insertion was searched and partially adapting the restoration was started. Premature polymerization by the operatory light must be prevented. Uniform pressure was applied on the occlusal surface, going from gentle to strong. c. During positioning of the partial crown, a mixture of bonding agent and composite was squeezed out at the margins. d. The excess of composite was removed at the margins with a probe. This push-squeeze procedure was repeated 2-3 times. e. The partial crown was stabilized with a finger. The margins were checked with a probe and the last composite excess was removed. If the margins disappear, the partial crown adapted well. f. Before polymerization, floss was placed interproximally to further remove excess luting composite. The restoration was stabilized with a finger. The floss was moved from the lingual towards the buccal side. This must be repeated until all composite excess is removed interproximally. g. A bit of composite was left on the easily accessible surfaces (buccal, palatal) but never in the interproximal area. h. The partial crown was stabilized with a smooth, rounded instrument. Each surface was polymerized for 20 s with a light intensity of 1200 mW/cm²: buccal, palatal, mesio-occlusal and disto-occlusal. i. Glycerine gel was applied at the margins. j. Re-polymerization of the luting composite after glycerine-gel application. Each accessible surface (buccal, palatal, mesio-occlusal and disto-occlusal) was polymerized again for 2 cycles of 20 s with a light intensity of 1200 mW/cm².

in a practice-based study of Collares et al,¹¹ where bonded ceramic inlay/onlays bonded with a simplified adhesive (2-step etch-and-rinse and 1-step self-etch adhesive) presented a risk of failure that is 142% higher than restorations bonded with adhesives that come with a bonding resin that is applied separately (3-step etch-and-rinse and 2-step self-etch adhesive). A similar conclusion was drawn by van Dijken and Hasselrot.⁹³

Finally, regular maintenance of the bonded ceramic restorations will lengthen their life span. The occlusion and articulation must be checked during recalls and corrected if needed. Rough areas must be re-polished to a high surface gloss, as they result more easily in the formation of cracks with a possible catastrophic failure as a long-term consequence. In addition, the ceramic-tooth interface must be carefully monitored, corrected and re-polished if needed.^{31,51,52,74}

Three clinical trials were found in the literature that evaluated the performance of nonretentive ceramic partial crowns after long-term clinical functioning (Table 1).^{5,7,40} The clinical protocols (preparation, adhesives, luting materials) were slightly different than the ones presented in this article. The survival rates varied between 96% and 100% after 7 to 10 years. Very few fractures occurred and almost any resto-

ration was lost. Next to the high success rate in these clinical trials, a very good long-term clinical performance is reported by Milichich.⁶⁴ He has bonded more than 3000 lithium-disilicate glass-ceramic partial crowns over a period of 9 years using a nonretentive prep design. Only 2 fractured restorations and no debonding incidents were reported.

CONCLUSION

All the above-mentioned positive results confirm the clinical effectiveness of the concept advanced in this article for the placement of bonded indirect ceramic restorations. Nevertheless, long-term controlled clinical trials are necessary to evaluate the proposed restoration type.

ACKNOWLEDGMENTS

The authors would like to express their gratitude to Mr. Claudio Tinti (MDT) for his meticulous work with the fabrication of the lithium-disilicate glass-ceramic partial crowns.

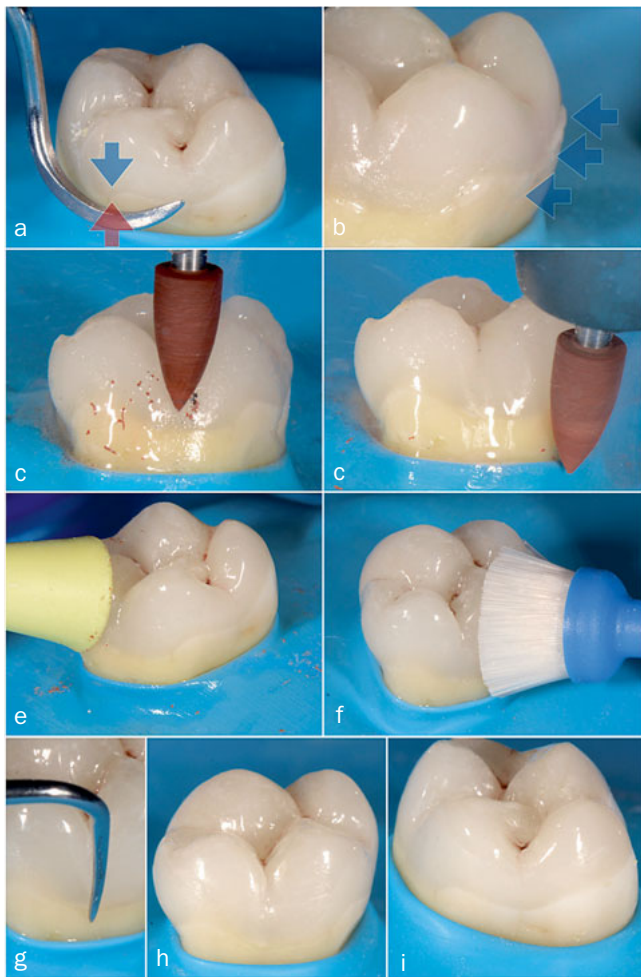
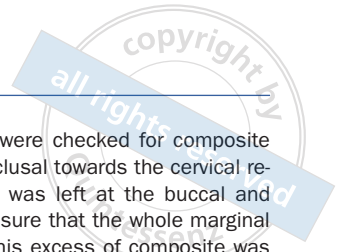


Fig 20 a. The interproximal margins were checked for composite excess with a sharp scaler from the occlusal towards the cervical region. b. A small excess of composite was left at the buccal and lingual margin (blue arrows), just to be sure that the whole marginal gap was filled with luting composite. This excess of composite was removed with polishing rubbers. c. A rubber polishing point, Brownie FG (Shofu Dental; Kyoto, Japan), was used under water cooling at low pressure and 15,000-20,000 rpm. The point removed the composite excess, which became visible by producing a brown powder. d. When powder production was no longer visible during the finishing procedure, all composite excess was removed. e. Polishing the margins to a high gloss was realised using a silicon yellow cup (Identoflex C9, KerrHawe) at a speed of 5000-7000 rpm, dry and with very low pressure. f. In a last step, the margins were cleaned and glossed with a soft synthetic brush. g. Using a sharp probe, the adaptation of the margins was checked. h and j. The restoration margins were invisible and non-probable.

Table 1 Overview of clinical trials that evaluated nonretentive ceramic partial crowns

Authors	Patient/restoration number	Material	Adhesive and luting composite	Duration (years)	Survival (%)	Fracture/debonding
Arnetzl et al ⁵	264/310	Vita Mark II	Syntac Classic & Variolink	8	96.5%	2 fractures (patient with bruxism); no debondings
Belleflamme et al ⁷	94/137	84 e.Max CAD 12 Vita Enamic 3 Composite (not specified)	IDS: Optibond FL Excite & Variolink	1-10 (±4.5)	99% e.Max CAD 89.9% Vita Enamic	2 debondings (all restorations included)
Guess et al ⁴⁰	25/80	40 ProCAD 40 e.Max Press	Syntac Classic & Tetric Ceram	7	97% ProCAD 100% e.Max Press	1 bulk fracture; no debondings

e.Max CAD, e.Max Press, ProCAD, Syntac Classic, Tetric Ceram, Excite, Variolink: Ivoclar Vivadent, Schaan, Liechtenstein; Vita Mark II, Vita Enamic: VITA Zahnfabrik, Bad Säckingen, Germany; Optibond FL: KerrHawe, Orange, CA, USA.

REFERENCES

- Acquaviva PA, Cerutti F, Adami G, Gagliani M, Ferrari M, Gherlone E, Cerutti A. Degree of conversion of three composite materials employed in the adhesive cementation of indirect restorations: a micro-Raman analysis. *J Dent* 2009;37:610–615.
- Ahlers MO, Mörig G, Blunck U, Hajto J, Pröbster L, Frankenberger R. Guidelines for the preparation of CAD/CAM ceramic inlays and partial crowns. *Int J Comput Dent* 2009;12:309–325.
- Arnetz GV, Arnetz G. Design for all-ceramic inlay materials. *Int J Comput Dent* 2006;9:289–298.
- Arnetz GV, Arnetz G. Biomechanical examination of inlay geometries – is there a basic biomechanical principle? *Int J Comput Dent* 2009;12:119–130.
- Arnetz GV, Arnetz G. Reliability of nonretentive all-ceramic CAD/CAM overlays. *Int J Comput Dent* 2012;15:185–197.
- Beier US, Kapferer I, Burtscher D, Giesinger J, Dumfahrt H. Clinical performance of all-ceramic inlay and onlay restorations in posterior teeth. *J Prosthodont* 2012;25:395–402.
- Belleflamme MM, Geerts SO, Louwette MM, Grenade CF, Vanheusden AJ, Mainjot AK. No post-no core approach to restore severely damaged posterior teeth: An up to 10-year retrospective study of documented endocrown cases. *J Dent* 2017;63:1–7.
- Belli R, Petschelt A, Hofner B, Hajto J, Sherrer SS, Lohbauer U. Fracture Rates and lifetime estimations of CAD/CAM all-ceramic restorations. *J Dent Res* 2016;95:67–73.
- Cekic-Nagas I, Canay S, Sahin E. Bonding of resin core materials to lithium disilicate ceramics: the effect of resin cement film thickness. *Int J Prosthodont* 2010;23:469–471.
- Clausen JO, Tara MA, Kern M. Dynamic fatigue and fracture resistance of non-retentive all-ceramic full-coverage molar restorations. Influence of ceramic materials and preparation design. *Dent Mater* 2010;26:533–538.
- Collares K, Corrêa MB, Laske M, Kramer E, Reiss B, Moraes RR, Huysmans MC, Opdam NJ. A practice-based research network on the survival of ceramic inlay/onlay restorations. *Dent Mater* 2016;32:687–694.
- D'Arcangelo C, Zarow M, De Angelis F, Vadini M, Paolantonio M, Giannoni M, D'Amario M. Five-year retrospective clinical study of indirect composite restorations luted with a light-cured composite in posterior teeth. *Clin Oral Invest* 2014;18:615–624.
- Dalphino PH, Francischone CE, Ishikiriama A, Franco EB. Fracture resistance of teeth directly and indirectly restored with ceramic materials. *Am J Dent* 2002;15:389–394.
- De Munck J, Mine A, Poitevin A, Van Ende A, Cardoso MV, Van Landuyt KL, Peumans M, van Meerbeek B. Meta-analytical review of parameters involved in dentin bonding. *J Dent Res* 2012;93:351–357.
- De Munck J, Van Meerbeek B, Yoshida Y, Inoue S, Vargas M, Suzuki K, Lambrechts P, Vanherle G. Four-year water degradation of total-etch adhesives bonded to dentin. *J Dent Res* 2003;82:136–140.
- Dejak B, Mlotkowski A. Three-dimensional finite element analysis of strength and adhesion on composite resin versus ceramic inlays on molars. *J Prosthodont* 2008;99:131–140.
- Dietschi D, Spreafico R. Evidence-based concepts and procedures for bonded inlays and onlays. Part I. Historical perspectives and clinical rationale for a biosubstitutive approach. *Int J Esthet Dent* 2015;10:210–227.
- Duarte JR S, Freitas CR, Saad JR, Sadan A. The effect of immediate dentin sealing on the marginal adaptation and bond strengths of total-etch and self-etch adhesives. *J Prosthodont* 2009;102:1–9.
- Elsayed A, Younes F, Lehmann F, Kern M. Tensile bond strength of so-called universal primers and universal multimode adhesives to zirconia and lithium disilicate ceramics. *J Adhes Dent* 2017;19:221–228.
- Federlin M, Hiller KA, Schmalz G. Controlled, prospective clinical split-mouth study of cast gold vs ceramic partial crowns: 5.5 years. *Am J Dent* 2010;23:161–167.
- Federlin M, Schmidt S, Hiller KA, Thonemann B, Schmalz G. Partial ceramic crowns: influence of preparation design and luting material on internal adaptation. *Oper Dent* 2004;29:560–570.
- Federlin M, Sipsos C, Hiller KA, Thonemann B, Schmalz G. Partial ceramic crowns. Influence of preparation design and luting material on margin integrity – a scanning electron microscopic study. *Clin Oral Invest* 2005;9:8–17.
- Feilzer AJ, De Gee AJ, Davidson CL. Increased wall-to-wall curing contraction in thin bonded resin layers. *J Dent Res* 1988;68:48–50.
- Feilzer AJ, De Gee AJ, Davidson CL. Setting stress in composite resin in relation to the configuration of the restoration. *J Dent Res* 1987;66:1636–1639.
- Felden A, Schmalz G, Hiller KA. Retrospective clinical study and survival analysis on partial ceramic crowns: results up to 7 years. *Clin Oral Invest* 2000;4:199–205.
- Felton DA, Kanoy BE, Bayne SC, Wirthman GP. Effect of in vivo crown margin discrepancies on periodontal health. *J Prosthet Dent* 1991;65:357–364.
- Fennis WM, Kuijts RH, Roeters FJ, Creughers NH, Kreulen CM. Randomized control trial of composite cuspal restorations: five-year results. *J Dent Res* 2014;93:36–41.
- Ferrari M, Köhen S, Grandini S, Ferrari Cagidiciaco E, Joda T, Discepoli N. Influence of cervical margin relocation (CMR) on periodontal health: 12 month results of a controlled trial. *J Dent* 2018;69:70–76.
- Frankenberger R, Hehn J, Hajto J, Krämer N, Naumann M, Koch A, Roggendorf MJ. Effect of proximal box elevation with resin composite on marginal quality of ceramic inlays in vitro. *Clin Oral Invest* 2013;17:177–183.
- Frankenberger R, Reinelt C, Petschelt A, Krämer N. Operator vs. material influence on clinical outcome of bonded ceramic inlays. *Dent Mater* 2009;25:960–968.
- Frankenberger R, Taschner M, Garcia-Godoy F, Petschelt A, Krämer N. Leucite-reinforced glass ceramic inlays and onlays after 12 years. *J Adhes Dent* 2008;10:393–398.
- Frankenberger R, Zeilinger I, Krech M, Mörig G, Naumann M, Braun A, Krämer N, Roggendorf MJ. Stability of endodontically treated teeth with differently invasive restorations: adhesive vs non adhesive cuspal stabilisation. *Dent Mater* 2015;31:1312–1320.
- Giannini M, Soares CJ, de Carvalho RM. Ultimate tensile strength of tooth structures. *Dent Mater* 2004;20:322–329.
- Goel KV, Khara SC, Gurusami S, Cheu RCS. Effect of cavity depth on stresses in a restored tooth. *J Prosthet Dent* 1992;67:174–183.
- Goldberg J, Güth JF, Magne P. Accelerated fatigue resistance of thick CAD/CAM composite resin overlays bonded with light-and dual-polymerizing luting resins. *J Adhes Dent* 2016;18:341–348.
- González-López S, De Haro-Gasquet F, Vilchez-Díaz MA, Ceballos L, Bravo M. Effect of restorative procedures and occlusal loading on cuspal deflection. *Oper Dent* 2005;30:33–38.
- González-López S, Vilchez Díaz MA, de Haro-Gasquet F, Ceballos L, de Haro Muñoz C. Cuspal flexure of teeth with composite restorations subjected to occlusal loading. *J Adhes Dent* 2007;9:11–15.
- Gregor L, Bouillaguet S, Onisor I, Ardu S, Krejci I, Rocca GT. Microhardness of light-and dual-polymerizable luting resins polymerized through 7.5mm-thick endocrowns. *J Prosthodont* 2014;112:942–948.
- Gresnigt MMM, Cune MS, de Roos JG, Özcan M. Effect of immediate and delayed dentin sealing on the fracture strength, failure type and Weibull characteristics of lithiumdisilicate laminate veneers. *Dent Mater* 2016;32:e73–81.
- Guess PC, Selz CF, Steinhart YN, Stampf S, Strub JR. Prospective clinical split-mouth study of pressed and CAD/CAM all-ceramic partial-coverage restorations: 7-year results. *Int J Prosthodont* 2013;26:21–25.
- Guess PC, Shultheis S, Wolkewitz M, Zhang Y, Strub JR. Influence of preparation design and ceramic thicknesses on fracture resistance and failure modes of premolar partial coverage restorations. *J Prosthodont* 2013;110:264–273.
- Hood JAA. Biomechanics of the intact, prepared and restored tooth: some clinical implications. *Int Dent J* 1991;41:25–32.
- Ilgstein I, Zitzmann NU, Bühler J, Weghaupt FJ, Attin T, Weiger R, Krastl G. Influence of proximal box elevation and the marginal quality and fracture behavior of root-filled molars restored with CAD/CAM ceramic or composite onlays. *Clin Oral Invest* 2015;19:1021–1028.
- Juloski J, Köken S, Ferrari M. Cervical margin relocation in indirect adhesive restorations. A literature review. *J Prosthodont Res* 2018;62:273–280.
- Kameyama A, Bonroy K, Elsen C, Lührs AK, Suyama Y, Peumans M, van Meerbeek B, De Munck J. Luting of CAD/CAM ceramic inlays: direct composite versus dual-cure luting cement. *Biomed Mater Eng* 2015;25:279–288.
- Kawai K, Ikenberg BP, Leinfelder KF. Effect of gap dimension on composite resin cement wear. *Quintessence Int* 1994;25:53–58.
- Kelly JR, Giordano R, Pober R, Cima MJ. Fracture surface analysis of dental ceramics: clinically failed restorations. *Int J Prosthodont* 1990;3:430–440.
- Kelly JR. Clinically relevant approach to failure testing of all-ceramic restorations. *J Prosthodont* 1999;81:652–661.
- Kielbassa AM, Philipp F. Restoring proximal cavities of molars using the proximal box elevation technique: Systematic review and report of a case. *Quintessence Int* 2015;46:751–764.
- Kim JH, Cho BH, Lee JH, Kwon SJ, Yi YA, Shin Y, Roh BD, Seo DG. Influence of preparation design on fit and ceramic thickness of CEREC 3 partial ceramic crowns after cementation. *Acta Odontol Scand* 2015;73:107–113.

51. Krämer N, Kunzelmann KH, Taschner M, Mehl A, Garcia-Goday F, Frankenberger R. Antagonist enamel wears more than glass ceramic inlays. *J Dent Res* 2006;85:1097–1100.
52. Krämer N, Taschner M, Lohbauer U, Petschelt A, Frankenberger R. Totally bonded ceramic inlays and onlays after eight years. *J Adhes Dent* 2008;10:307–314.
53. Krifka S, Anthofer T, Fritsch M, Hiller KA, Schmalz G, Federlin M. Ceramic inlays and partial ceramic crowns: influence of remaining cusp wall thickness on the marginal integrity and enamel crack formation in vitro. *Oper Dent* 2009;34:32–42.
54. Laegreid T, Gjerdet NR, Johansson AK. Extensive composite molar restorations: 3 years clinical evaluation. *Acta Odontol Scand* 2012;70:344–352.
55. Lyann SK, Takagaki T, Nikaido T, Uo M, Ikeda M, Sadr A, Tagami J. Effect of different surface treatments on the tensile bond strength to lithium disilicate glass ceramics. *J Adhes Dent* 2018;20:261–268.
56. Ma Li, Guess PC, Zhang Y. Load-bearing properties of minimal-invasive monolithic disilicate and zirconia occlusal onlays: Finite element and theoretical analyses. *Dent Mater* 2013;29:742–751.
57. Magne P, Belsler UC. Porcelain versus composite inlays/onlays: effects of mechanical loads on stress distribution, adhesion and crown flexure. *Int J Periodontics Restorative Dent* 2003;23:543–555.
58. Magne P, Kim TH, Cascione D, Donovan TE. Immediate dentin sealing improves bond strength of indirect restorations. *J Prosthet Dent* 2005;94:511–519.
59. Magne P, Oganasyan T. CT-scan-based finite element analysis of premolar cuspal deflection following operative procedures. *Quintessence Int* 2009;29:361–369.
60. Magne P, Schlichting LH, Maia HP, Baratieri LN. In vitro fatigue resistance of CAD/CAM composite resin and ceramic posterior occlusal veneers. *J Prosthet Dent* 2010;104:149–157.
61. Magne P, Spreafico RC. Deep margin elevation: a paradigm shift. *Am J Esthet Dent* 2012;2:86–96.
62. Magne P, Stanley K, Schlichting LH. Modeling of ultrathin occlusal veneers. *Dent Mater* 2012;28:777–782.
63. Magne P. Immediate dentin sealing: a fundamental procedure for indirect bonded restorations. *J Esthet Restor Dent* 2005;17:144–155.
64. Milichic G. The compression dome concept: the restorative implications. *Gen Dent* 2017;65:55–60.
65. Molin MK, Karlsson SL, Kristiansen MS. Influence of film thickness on joint bend strength of a ceramic/resin composite joint. *Dent Mater* 1996;12:245–249.
66. Mondelli J, Sene F, Ramos R, Benetti AR. Tooth structure and fracture strength of cavities. *Braz Dent J* 2007;18:134–138.
67. Morimoto S, Rebello de Sampaio FBW, Braga MM, Sesma N, Özcan M. Survival rate of resin and ceramic inlays, onlays, and overlays: A systematic review and meta-analysis. *J Dent Res* 2016;95:985–994.
68. Opdam NJ, van de Sande FH, Bronkhorst E, Cenci MS, Bottenberg P, Pallesen U, Gaengler P, Lindberg A, Huysmans MC, van Dijken JW. Longevity of posterior composite restorations: a systematic review and meta-analysis. *J Dent Res* 2014;93:943–949.
69. Opdam NJM, Frankenberger R, Magne P. From direct versus indirect towards an integrated restorative concept in the posterior region. *Oper Dent* 2016;7:S27–S34.
70. Panitvisai P, Messer HH. Cuspal deflection in molars in relation to endodontic and restorative procedures. *J Endodont* 1995;2:57–61.
71. Park SH, Lee CS. The difference in degree of conversion between light-cured and additional heat-cured composites. *Oper Dent* 1996;21:213–217.
72. Peumans M, De Munck J, Mine A, Van Meerbeek B. Clinical effectiveness of contemporary adhesives for the restoration of non-carious cervical lesions. A systematic review. *Dent Mater* 2014;30:1089–1103.
73. Peumans M, Valjakova EB, De Munck J, Mishevska CB, Van Meerbeek B. Bonding effectiveness of luting composites to different CAD/CAM materials. *J Adhes Dent* 2016;18:289–302.
74. Peumans M, Voet M, De Munck J, Van Landuyt K, Van Ende A, Van Meerbeek B. Four-year clinical evaluation of a self-adhesive luting agent for ceramic inlays. *Clin Oral Investig* 2013;17:739–750.
75. Politano G, Fabianelli A, Papacchini F, Cerutti A. The use of bonded partial ceramic restorations to recover healthy compromised teeth. *Int J Esthet Dent* 2016;11:314–336.
76. Qanungo A, Aras MA, Chitre V, Mysore A, Amin B, Daswani SR. Immediate dentin sealing for indirect bonded restorations. *J Prosthodont Res* 2016;60:240–249.
77. Reeh E, Messer H, Douglas WH. Reduction in tooth stiffness as a result of endodontic and restorative procedures. *J Endodont* 1989;15:512–516.
78. Rocca GT, Rizcalla N, Krejci I, Dietschi D. Evidence-based concepts and procedures for bonded inlays and onlays. Part II. Guidelines for cavity preparation and restoration fabrication. *Int J Esthet Dent* 2015;10:392–413.
79. Roggendorf MJ, Krämer N, Dippold C, Vosen VE, Naumann M, Jablonski-Momeni A, Frankenberger R. Effect of proximal box elevation with resin composite on marginal quality of resin composite inlays in vitro. *J Dent* 2012;40:1068–1073.
80. Roggendorf MJ, Kunzi K, Eber J, Roggendorf HC, Frankenberger R, Reich SM. Seven-year clinical performance of CEREC 2 all-ceramic CAD/CAM restorations places within deeply destroyed teeth. *Clin Oral Invest* 2012;16:1413–1424.
81. Rosentritt M, Preis V, Behr M, Hahnel S, Handel G, Kolbeck C. Two-body wear of dental porcelain and substructure oxide ceramics. *Clin Oral Investig* 2012;16:935–943.
82. Sarr M, Mine A, De Munck J, Cardoso MV, Kane AW, Vreven J, Van Meerbeek B, Van Landuyt KL. Immediate bonding effectiveness of contemporary composite cement to dentin. *Clin Oral Invest* 2010;14:569–577.
83. Sasse M, Krummel A, Klosa K, Kern M. Influence of restoration thickness and dental bonding surface on the fracture resistance of full-coverage occlusal veneers made from lithium disilicate. *Dent Mater* 2015;31:907–915.
84. Schlichting LH, Maia HP, Baratieri NL, Magne P. Novel-design ultra-thin CAD/CAM composite resin and ceramic occlusal veneers for the treatment of severe dental erosion. *J Prosthet Dent* 2011;105:217–226.
85. Scholtanus JD, Özcan M. Clinical longevity of extensive direct composite restorations in amalgam replacement: up to 3.5 years follow-up. *J Dent* 2014;42:1404–1410.
86. Silva NR, de Souza GM, Coelho PG, Stappert CF, Clark EA, Rekow ED, Thompson VP. Effect of water storage time and composite cement thickness on fatigue of a glass-ceramic trilayer system. *J Biomed Mater Res B Appl Biomater* 2008;84:117–123.
87. St-Georges AJ, Sturdevant JR, Swift EJ Jr, Thompson JY. Fracture resistance of prepared teeth restored with bonded inlay restorations. *J Prosthet Dent* 2003;89:551–557.
88. Stappert CFJ, Abe P, Kurths V, Gerds T, Strub JR. Masticatory fatigue, fracture resistance, and marginal discrepancy of ceramic partial crowns with and without coverage of compromised cusps. *J Adhes Dent* 2008;10:41–48.
89. Stappert CFJ, Att W, Gerds T, Strub JR. Fracture resistance of different partial-coverage ceramic molar restorations. *J Am Dent Assoc* 2006;137:514–522.
90. Tantbirojn D, Versluis A, Pintado MR, DeLong R, Douglas WH. Tooth deformation patterns in molars after composite restoration. *Dent Mater* 2004;20:535–542.
91. Tian T, Tsoi JK, Matinlinna JP. Aspects of bonding between resin luting cement and glass ceramic materials. *Dent Mater* 2014;30:e147–162.
92. van de Sande FH, Opdam NJ, Da Rosa Rodolpho PA, Correa MB, Demarco FF, Cenci MS. Patient risk factors' influence on survival of posterior composites. *J Dent Res* 2013;92:78S–83S.
93. Van Dijken JW, Hasselrot L. A prospective 15-year evaluation of extensive dentin-enamel bonded pressed ceramic coverages. *Dent Mater* 2010;26:929–939.
94. Veneziani M. Adhesive restorations in the posterior area with subgingival cervical margins: new classification and differentiated treatment approach. *Eur J Esthet Dent* 2010;5:50–76.
95. Wendler M, Belli R, Valladares D, Petschelt A, Lohbauer U. Chairside CAD/CAM materials. Part 3: Cyclic fatigue parameters and lifetime predictions. *Dent Mater* 2018;34:910–921.
96. Zaruba M, Kasper R, Kazama R, Wegehaupt FJ, Ender A, Attin T, Mehl A. Marginal adaptation of ceramic and composite inlays in minimally invasive mod cavities. *Clin Oral Invest* 2014;18:579–587.

Clinical relevance: Fundamental for long-term functioning, a bonded lithium-disilicate glass-ceramic partial crown requires a nonretentive antifragile tooth preparation with a smooth surface and a well-defined prep margin in combination with a correct adhesive and luting procedure.